Effect of humerus fractures on blood flow velocity in the upper limb and brain

Review article/Artykuł poglądowy © J ORTHOP TRAUMA SURG REL RES 1 (34-35) 2014

V. A. Schurov, F. A. Matsukatov, E. O. Darvin

Russian Ilizarov Scientific Center for Restorative Traumatology and Orthopaedics
Director of Research Center: Alexander V. Gubin

Address for correspondence/ Adres do korespondencji:
V. A. Schurov
St. Maria Ulyanova 6
640014, Kurgan, Russia
e-mail: Shchurovland@mail.ru

Received: 15.05.2013
Accepted: 24.07.2013
Published: 15.03.2014

STATISTIC STATYSTYKA	
Word count Liczba słów	1328
Tables Tabele	1
Figures Ryciny	6
References Piśmiennictwo	12

Summary

The work carried out to analyze the reaction centers of the brain in the treatment of patients with humeral fracture. Systolic linear blood flow velocity in the brachial and middle cerebral artery was measured in 18 patients with humeral fracture treated with the Ilizarov external fixation using Doppler ultrasound to assess hypothesis of changes in the functional condition of cerebral centres. The age of patients from 22 to 86 years. In patients during treatment and after it conducted psychophysiological testing (test SF-36).

Blood flow was shown to accelerate in both the brachial artery (123%) and the middle cerebral artery from the opposite side (137%) within 2 to 4 weeks of the bone fixation. The increase was dependent on intensity of the pain and was shown to be less in middle adulthood and elderly patients. Blood flow velocity was shown to increase in the arteries of injured segment and the middle cerebral artery of the contralateral side during humerus fracture repair. Amount of accelerated blood velocity caused by limb injury in the middle cerebral artery of the contralateral side was shown to decrease with increased patients' age due to low reactivity of the brain arteries.

Key words: fractured shoulder, transosseous osteosynthesis. blood flow of the brain

Systolic linear blood flow velocity in the brachial and middle cerebral artery was measured in 18 patients with humeral fracture treated with the Ilizarov external fixation using Doppler ultrasound to assess hypothesis of changes in the functional condition of cerebral centres. Blood flow was shown to accelerate in both the brachial artery (23%) and the middle cerebral artery from the opposite side (37%) within 2 to 4 weeks of the bone fixation. The increase was dependent on intensity of the pain and was shown to be less in middle adulthood and elderly patients.

A limb Injury is known to be not only a local process. There is a notion of traumatic disease involving nervous, humoral and immune systems into pathological process [1, 2]. Functional condition of different parts of the brain in patients can be evaluated by intensity of blood supply. Blood supply to the brain has several specific features. Normal neuron activity can be maintained with relatively high intensity of blood supply to the brain (50 ml/min per 100 g of tissue) that is stable even with altered systemic hemodynamics [3]. Overall cerebral blood supply is permanent due to the fact that if a considerable increase occurs in one of the parts of the brain, a compensated decrease takes place in other parts [4, 5]. Cerebral blood supply tends to increase temporarily from intense mental or physical exertion [6, 7]. The studies of cerebral blood supply performed during management of lower limb fractures showed steady increase in the blood flow velocity in both the injured organ and the middle cerebral artery (MCA) of the contralateral side [8].

Humerus fractures account for 5% of the total skeletal injuries. Closed Ilizarov external fixation can be the best option for humerus fractures due to less traumatic procedure providing accurate bone reduction and reliable fixation throughout the whole period of treatment to complete bone healing [9].

The present study is designed to assess stimulation of blood flow velocity in the MCA during Ilizarov treatment of patients with closed humerus injury, duration and amount of increase in the cerebral blood flow velocity, relations between the changed figure and condition of regional blood flow and patient's age.

MATERIAL AND METHODS OF STUDY

Peak systolic blood flow velocity (BFV) was measured in the humeral arteries (with 8MHz transducer) and in the anterior, posterior and meddle arteries of the brain bilaterally (with 2 MHz transducer) using Angiodin-2KM computerized diagnostic device (BIOSS manufacturing, Russia). The study focused on BFV in the MCA, providing blood to the parietal lobe and major part of the brain. To evaluate MCA vasomotor reactivity index BFV variations were measured with functional tests of arbitrary breath holding and hyperpnea [10]. All patients were surveyed the Short Form Health Survey (SF-36) during the treatment and on completion.

Twenty three patients with closed humerus fractures were reviewed during treatment with the Ilizarov external fixation and after the treatment was accomplished. The patients' age ranged from 22 years to 86 years (mean 48±6).

RESULTS OF THE STUDY AND DISCUSSION

Linear BFV in the vessels of upper limb was shown to be the highest in the brachial artery, less in the radial and the least in the ulnar artery (Table 1). No considerable growth in the figures was observed in the involved side as compared to the intact one. The reason is that volumetric blood flow rate of the fractured limb is regulated mainly by changed arterial lumen that allows for maintaining optimal structure of the blood flow in the vessels of different diameter and wall characteristics.

Tab. 1. Blood flow velocity in the arteries of patients (18) during treatment (M±m)

Side	Upper limb arteries (cm/s)			Cerebral arteries (cm/s)		
	Brachial	Radial	Ulnar	Anterior	Middle	Posterior
Involved	**62.9** ±6.0	**49.3** ±3.7	**31.8** ±5.7	**86.5** ±7.6	**69.9** ±5.3	**65.7** ±4.2
Contra-lateral	**61.7** ±4.4	**43.3** ±3.1	**39.0** ±9.4	**82.8** ±6.6	**78.1** ±9.1	**63.9** ±5.2

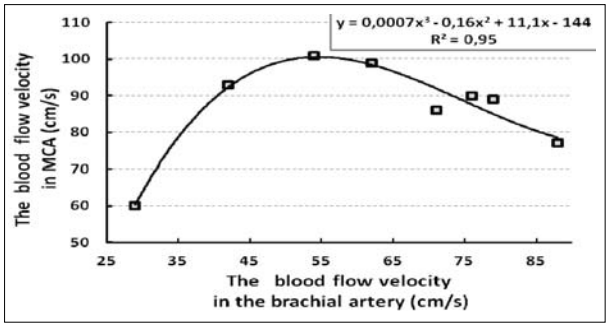

Fig. 1. Correlation between relative blood flow velocity in the brachial artery and in the MCA of the contralateral side

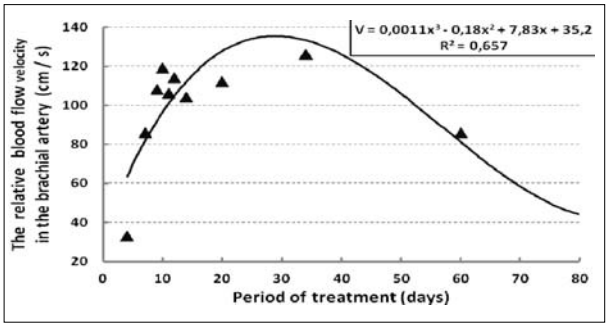

Fig. 2. Dynamics in the relative blood flow velocity of the brachial artery during treatment

No considerable changes were revealed in BFV of the anterior and posterior cerebral arteries during treatment of patients with humerus fractures. Linear BFV showed increase in the MCA of the contralateral side as compared to the injured humerus. Correlation between BFV of the contralateral and ipsilateral cerebral sides can be described by linear regression equation, $\mathbf{V_k = 4{,}44 + 1{,}05 * V_i;}$ **r=0,617**. The increased brachial artery BFV to 55 cm/s led to enhanced BFV in the MCA of the contralateral side (Fig. 1). However, further increase in the regional blood flow resulted in the decrease of the cerebral blood supply.

BFV in the brachial artery of the broken limb was shown to prevail over BFV of the intact limb mostly throughout the second week of fixation and measured 23% on average (Fig. 2).

Relative BFV in the MCA of the contralateral side was shown to increase during the first 2 to 4 weeks of the bone external fixation, measuring 137% on average, and then get to normal values (Fig. 3).

Cerebral blood supply measurements were dependent on both length of treatment and patients' age. Maximum increase in BFV of the MCA was observed in the contralateral side of adolescents and young adults (Fig.4). Selective redistribution of blood in cerebral vessels was absent in most of the patients over the age of 50.

To understand the reason of increased blood flow velocity in the blood arteries of the brain with limb injury MCA vasomotor reactivity (VMR) index is to be analyzed. With increase in the blood flow velocity of MCA VMR index was shown to decrease (Fig.5). Functional tests of arbitrary breath holding indicated to lower blood carbon dioxide level. Hence, we can conclude that one of the reasons for increased blood flow velocity in the blood arteries of the brain at rest was higher metabolic activity in tissues, higher demand for oxygen and accumulation of carbon dioxide in the blood.

Correlation between BFV of MCA in the contralateral and injured sides was shown to increase with enhanced pain affecting capability daily activity (Fig. 6) that was revealed with the short form 36 health survey questionnaire (SF-36). Long-term follow-ups showed no greater BFV of MCA in the contralateral side with increased pain intensity while blood flow velocity showed higher values in the contralateral side during the fixation period.

Therefore, metabolic and hemodynamic changes were shown to occur in the tissues of injured limb and corresponding structures of the central nervous system that are responsible for controlling the limb during the healing of the broken humerus with Ilizarov external fixation. Blood flow in the arteries of the limb was shown to norma-

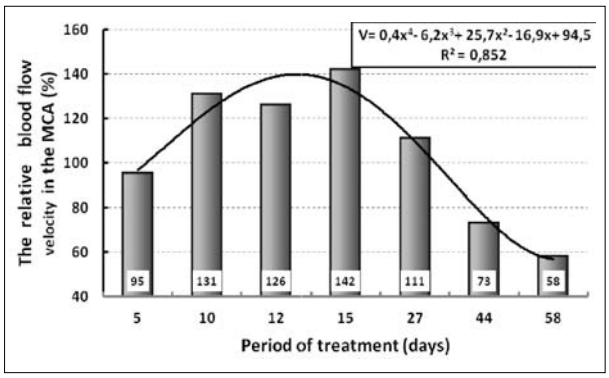

Fig. 3. Dynamics in the relative BFV of the MCA at the contralateral side of the brain during treatment of the patients

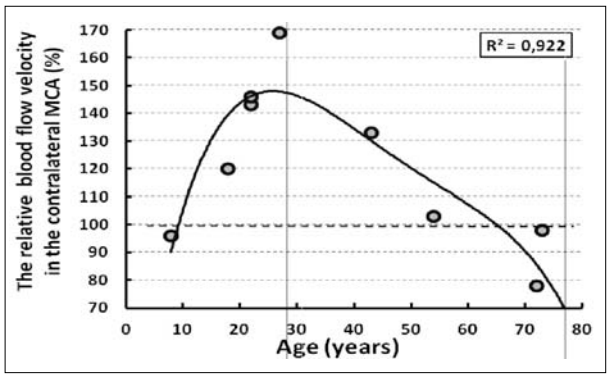

Fig. 4. Age-related dynamics in relative BFV of the MCA at the contralateral side of the brain

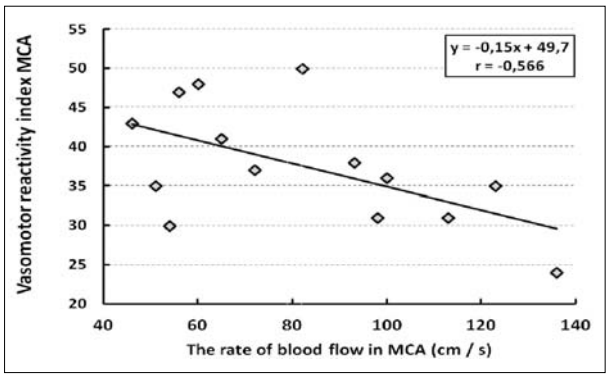

Fig. 5. Correlation between vasomotor reactivity index and blood flow velocity of MCA in patients with humerus fracture

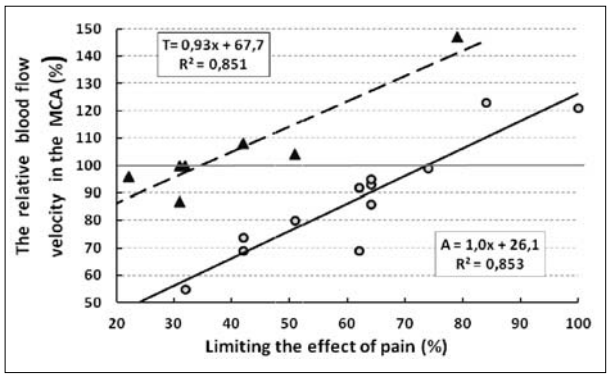

Fig. 6. Correlation between limiting the effect of pain and relative BFV of MCA in the contralateral side during treatment (F) and after the treatment (I)

lize, pain syndrome relieved and effect of accelerated blood flow of MCA in the contralateral side subsided during consolidation of bone fractures. Dynamics and outcome of treatment of limb injuries and diseases appeared to be determined by both the condition of injured tissues and regulating centres of the brain that control movements where changes occur as well. These changes in the brain structures controlling the limb can influence metabolic processes in the limb tissues and their reparative capabilities.

It is important to adequately induce functional condition of the brain. The presence of external fixation device applied to a leg can be considered an induction, and it is helpful to combine the processes of therapeutic and functional rehabilitation, locomotor activity of the patients, exercise therapy sessions, massage in time etc. Increased proprioceptive afference of involved organs must be favourable for both tissues of the limbs and the condition of the nerve centres controlling them.

G.A.Ilizarov [11] searched for theoretical substantiation of mechanisms that were clinically revealed as having stimulating effects of external fixation device, locomotor activity of patients, adequately accelerated blood flow on reparative bone regeneration. Different local mechanical physical and biological factors were considered. Reflectory interaction between the brain and the periphery was not in the focus of the study. The concept of interaction between the brain and the injured peripheral anatomical formations are consistent with principle theoretical considerations of A.D.Speransky about a trophic role of the central nervous system [12].

CONCLUSIONS

1. Blood flow velocity was shown to increase in the arteries of injured segment and the middle cerebral artery of the contralateral side during humerus fracture repair.
2. Amount of accelerated blood velocity caused by limb injury in the middle cerebral artery of the contralateral side was shown to decrease with increased patients' age due to low reactivity of the brain arteries.

References:

1. *Pasternak G.W. The central questions in pain perception may be peripheral // Anesth. Analg. 1998; V. 87: ą 2. P. 388-393.*
2. *Kornilov N.V., Avrunin Ŕ.S. Travmaticheskaya bolezn' – metabolicheskoe narushenie organnykh kompartmentov (Traumatic disease – metabolic disorder of organ compartments) (In Russian) //Proceedings of Acad.I.P.Pavlov MU. 2001; Ň.VIII: ą 3. 120-122.*
3. *Faraci F.M., Heistad D.D. Regulation of the Cerebral Circulation: Role of Endothelium and Potassium Channels. // Physiological Reviews. 1998; Vol. 78: No 1. January. 53-97.*
4. *Baumbach G.L., Heistad D.D. Effects of sympathetic stimulation and changes in arterial pressure on segmental resistance of cerebral vesselsin rabbits and cats. // Circ. Res. 1983; 52: 527-533.*
5. *Gannushkina I.V. Fiziologiya I Fiziologiya I patofiziologiya mozgovogo krovoobrascheniya (Physiology and pathophysiology of the cerebral blood supply) (In Russian). In: Sosudistye zabolevaniya nervnoy sistemy (Vascular diseases of the nervous system) /Edited by E.V.Schmidt/. Ĕ., Meditsina. 1975; 65-106.*
6. *Kulikov V.N., Doronina N.L Reaktsiya mozgovogo krovoobrascheniya na legkuyu fizicheskuyu nagruzku (Reaction of cerebral blood supply to light physical activity) (In Russian) // Fiziolog. cheloveka, 1999; V. 35: ą 6. 71-75.*
7. *Hellstrom G., Wahlgren N.G. Physical exercise increases middle cerebral artery blood flow velocity //Neurosurg. Rev., 1993. V. 16. N 2. –p. 151.*
8. *Shchurov V.A., Gubin A.V. The influence of trauma on the limb blood flow through the vessels of the brain. Czech Republic. Prague. // Materialy VIII miedzynarodowey naukowy-practyczney konferencyu. 2012; Medycyna. V 17: 80-83.*
9. *Shevtsov V.I., Shved S.I., Sysenko Yu.M. Lechenie bolnykh s perelomami plechevoy kosti I ikh posledstviyami metodom chreskostnogo osteosinteza (Treatment of patients with humerus fractures and their sequelae using transosseous osteosynthesis technique) (In Russian). Kurgan, 1995; 224 p.*
10. *Ultrazvukovaya diagnostika sosudistykh zabolevaniy (Ultrasound diagnosis of vascular diseases) (In Russian). (Manual edited by V.P.Kulikov). Moscow. ÎÎÎ «Strom». 2007: 512.*
11. *Ilizarov G.A. Nekotorye teoreticheskie I klinicheskie aspekty chreskostnogo osteosinteza s pozitsiy otkrytykh name obschebiologicheskikh zakonomernostey (Some theoretical and clinical aspects of transosseous osteosynthesis with regard to general biological regularities we discovered) (In Russian) //Experimental and clinical aspects of transosseous osteosynthesis that are being developed at KNIIEKOT. Book of abstracts. Kurgan, 1986; 7-12.*
12. *Speransky A.D. Nervnaya trofika v teorii I praktike meditsiny (Nervous trophics in medical practice) (In Russian). Ĕ., VIEM. 1936; 423 .*