The Journal of Orthopaedics Trauma Surgery & Related Research

# Surgery of the Lateral Rays

© J ORTHOP TRAUMA SURG REL RES 4 (12) 2008
Review article

LOUIS SAMUEL BAROUK*, PIERRE BAROUK**
* 39, Chemin de la Roche, 33370, Yvrac, France
** Clinique St Antoine de Padoue Rue Walter Poupot, Bordeaux, France
www.barouk-ls-p.com

Address for correspondence/Adres do korespondencji:
39, Chemin de la Roche, 33370, Yvrac, France

**Statistic**

| | |
|---|---|
| Word count | 1808 |
| Tables | 0 |
| Figures | 10 |
| References | 5 |

Received: 01.08.2008
Accepted: 02.09.2008
Published: 01.10.2008

**Summary**
Authors described technical details of forefoot reconstruction by metatarsals osteotomies as Weil and BRT (Barouk, Rippstein, Toullec). Additionally the clow toes local surgery is discussed.
**Key words:** forefoot reconstruction, toes deformities, metatarsalgia, Weil osteotomy, BRT osteotomy

## INTRODUCTION

There are three main static problems usually encountered in the lateral rays: metatarsalgia, claw toes, and MTP problems, notably dislocation.

Our aim is above all to detail the surgical techniques we perform to treat these problems, and to expose their indications and results.

## TECHNIQUES, GENERALITIES

***The soft tissue surgery*** has always to be performed,

- On the *tendons,* particularly the *lengthening* of the long extensor and long flexor tendons, but the transfer of the tendons seems to be not required
- On the *joints*, notably in MTP and interphalangeal joints.
- However, this surgery is just complementary to the osteotomies, which are required in most of cases.

**The Osteotomies**

Among many proposed Osteotomies, our choice are:

- Distal Osteotomies, with notably the *Weil Osteotomy,* and the percutaneous osteotomy
- Basal Osteotomies, notably the *BRT osteotomy*.

## WEIL OSTEOTOMY

Some words on the ***history in Europe***: during the 1st Scarf meeting (in Bordeaux, 1992), LS Weil made his osteotomy for the first time in Europe, during a live surgery.

From this time, the Weil osteotomy was spreaded, in France as well as in the world.

**Fig. 1.** The three main pathologies of the lateral rays

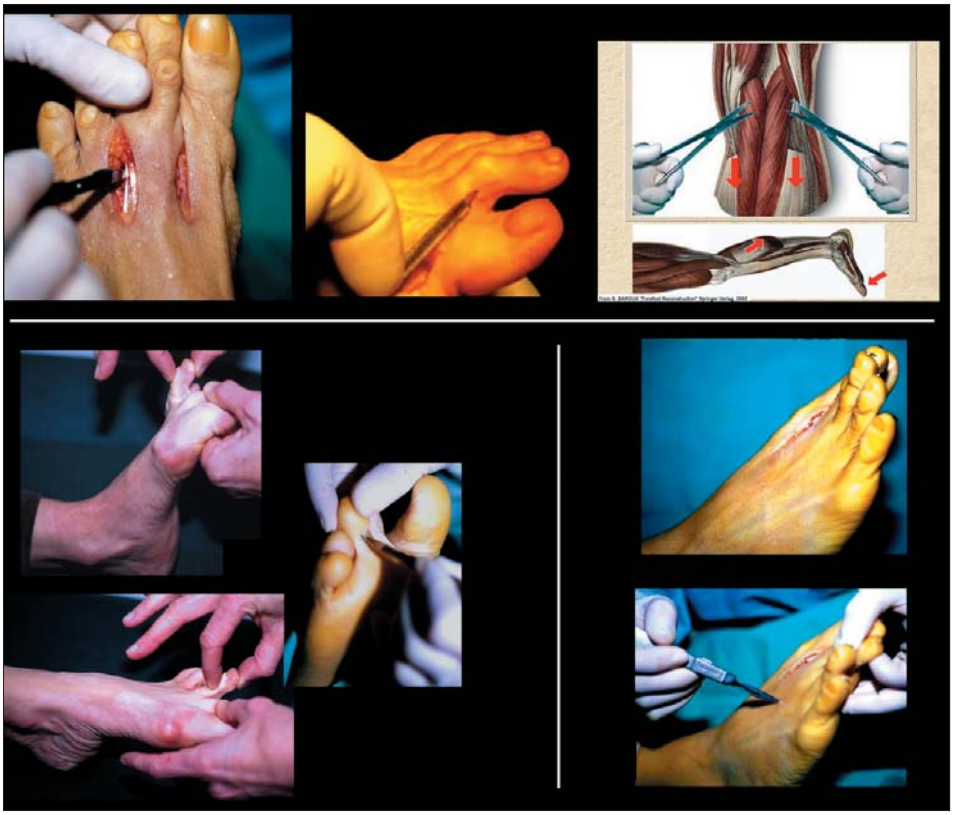

**Fig. 2.** Soft tissue surgery
*Upper line.* Complementary lateral release after Weil osteotomy. PIP plantar release. Gastrocnemius proximal release
*Bottom, Left:* Flexor tendon shortness: assessment and percutaneous distal section
*Bottom, Right:* extensor tendon shortness, well assessed after toe K. Wiring: percutaneous section

***Our aim*** is to bring precisions on the ***technical main points***, in order to avoid problems, and to specify its indications.

The Weil osteotomy is a proximal sliding of the metatarsal head; we have first to determine ***preoperatively how far the metatarsal shortening*** (Fig. 3), on the dorsal plantar X-ray and on the oblique medial view: this assessment is made thanks to the ***ms*** point (see also our article "Scarf Osteotomy"), focused on the most deformed or dislocated MTP Joint. This assessment, combined with the respect of the metatarsal parabola, allows to determine accurately the metatarsal shortening, both on the most deformed rays and on the other metatarsals, so that we can assess how many metatarsals have to be shortened

**Operative technique**

It is detailled in the Figure 5; we describe the successive steps: **1**. the approach , **2**. the cut, **3**. the distal resection to reach a correct parabola (including the first metatarsal shortening if required) **4**. the double layer **5**. the fixation. After the osteotomy, soft tissue surgery in most of cases (see above)

**Postoperative period** (Fig. 6)

One month with bandage and self training during 3 to 5 months are critical to obtain a good MTP range motion as well as a correct toe ground contact. Patients walk with the heel support shoe for 4 to 6 weeks, depending on the metatarsal head quality

**Problems encountred** (Fig. 7)

Usually, Surgeons are immediately enthusiastic during their first experience of the Weil osteotomy, then appear their critics and hesitations, mainly in relation to the MTP stiffness occurring post operatively, which particularly decrease the toe ground contact. Of course, we have also got these problems, but we brought reliable solutions both to avoid and to treat them.

***MTP stiffness*: *how to avoid***

We observed that MTP stiffness occurs in the following situations:

- *shortening less than 8 mms*,
- no respect of the *metatarsal parabola*.
- no respect *of the ms point.*
- no preservation of *dorsal soft tissues* on the metatarsal
- no *double layer* performed
- *screw too distal*
- insufficiency of bandaging or training

An accurate management allows easily to eliminate these causes of tighteness.

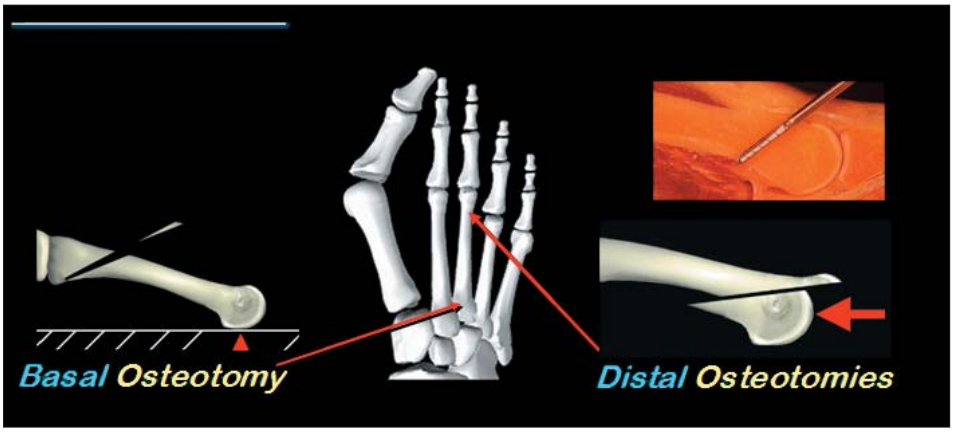


**Fig. 3.** ***The three osteotomies we use***: basal (BRT), distal: Weil, and percutaneous

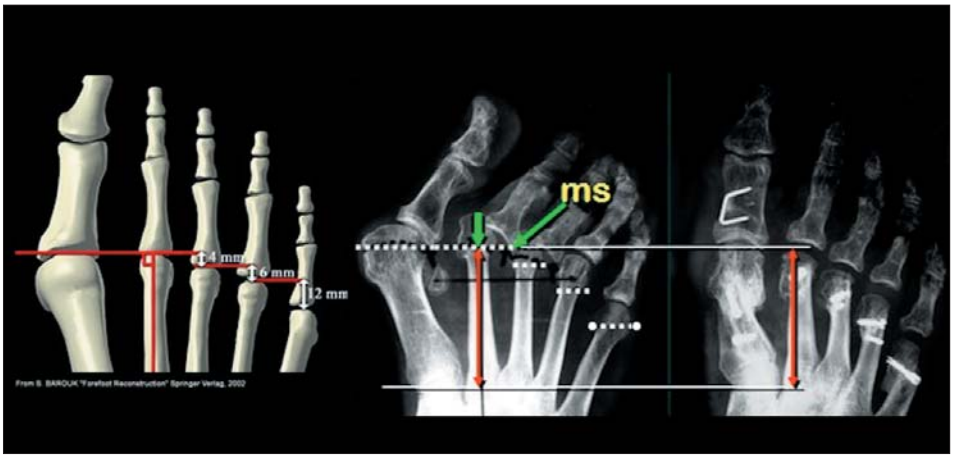


**Fig. 4.** ***The ms point*** is located on the proximal part of the phalanx of the most deformed ray. Its projection on the corresponding metatarsal indicates the shortening to be done if we want a good and long lasting Correction. Then the other metatarsals are shortened if required ,following the metatarsal curve

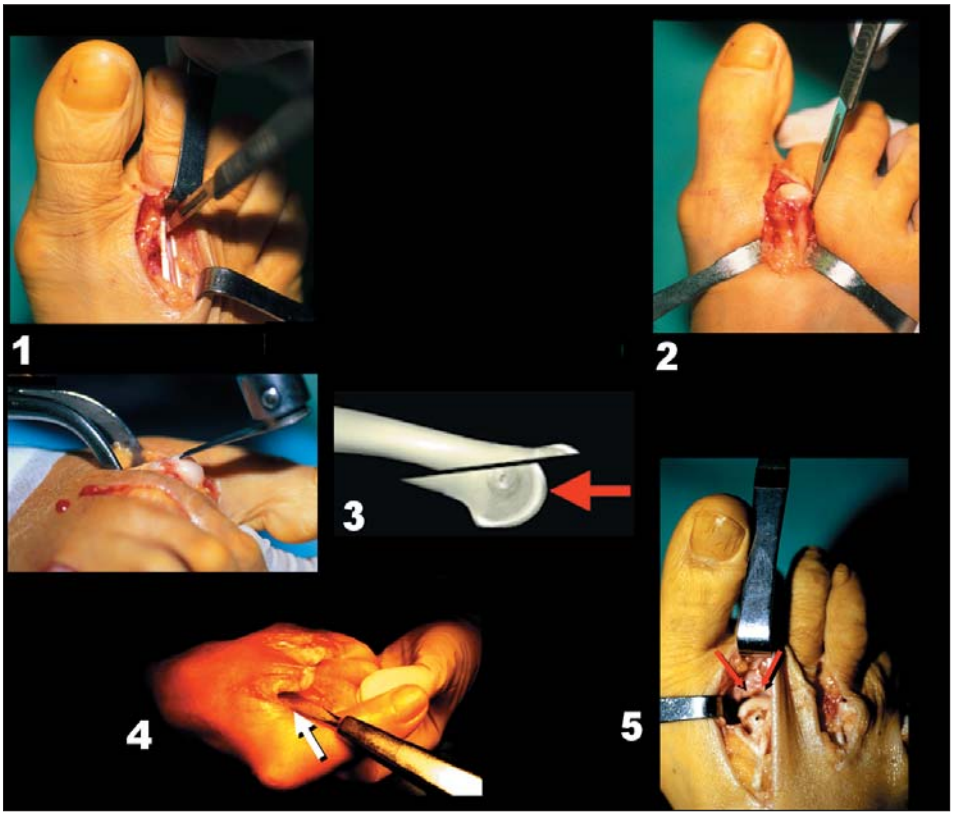


**Fig. 5a.** Weil osteotomy: approach, first cut, head release
*Upper line:* approach between the two extensor tendons, section of the collateral ligaments, cut the more dorsal and horizontal
*Bottom:* the head has to be free to have a proximal sliding such as for example a MTP dislocation be corrected without tension

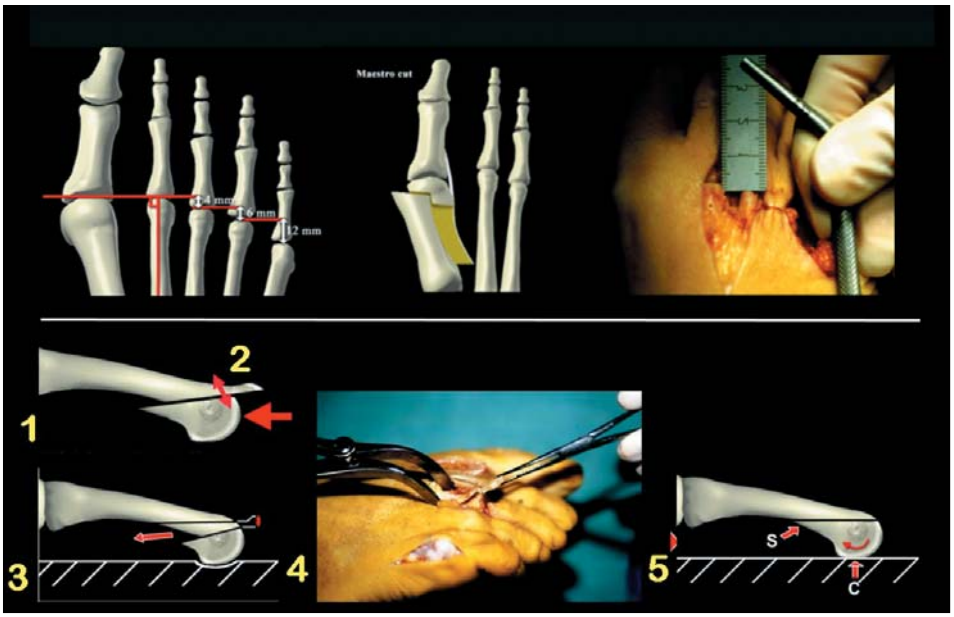


**Fig. 5b.** Weil osteotomy: metatarsal parabola, second layer.
*Upper line:* distal metatarsal resection and adjustement of the relative length of the metatarsals
*Botom:* the second layer is performed only after the distal resection


**Fig. 5c.** Weil osteotomy: fixation
While preserving the dorsal soft tissues, we fix the osteotomy with a twist off screw or a FRS 2. 5 screw, introduced 1 cm proximally from the distal edge

***MTP Stiffness*: *how to treat:***
One postoperative year, once corrected if required the situations above described just make *per cutaneous or mini-invasive MTP dorsal release; small surgery, excellent results.*

***Metatarsalgia*** (recurrent, remaining):
Similarly, once corrected major local problem, Make BRT osteotomy (basal metatarsal elevation) at one post operative year.

**Indications and results** (Fig. 8)

- Above all ***MTP dislocation***. All authors are according to consider the Weil Osteotomy as the best procedure. Nevertheless, complete and long lasting correction is only obtained when the ***ms*** point is respected.
- ***Severe metatarsalgia***. In this case, soft tissue procedure, claw toe correction, Hallux valgus correction are insufficient. Elevation osteotomy of the metatarsals (BRT) is similarly insufficient if the metatarsalgia is severe, so that the Weil osteotomy is required.

**Fig. 6.** Postoperative period after Weil osteotomy
The heel support shoe: 3 to 5 weeks.
Training, bandage: the toe has to be pulled or pushed in plantar flexion, during 6 weeks

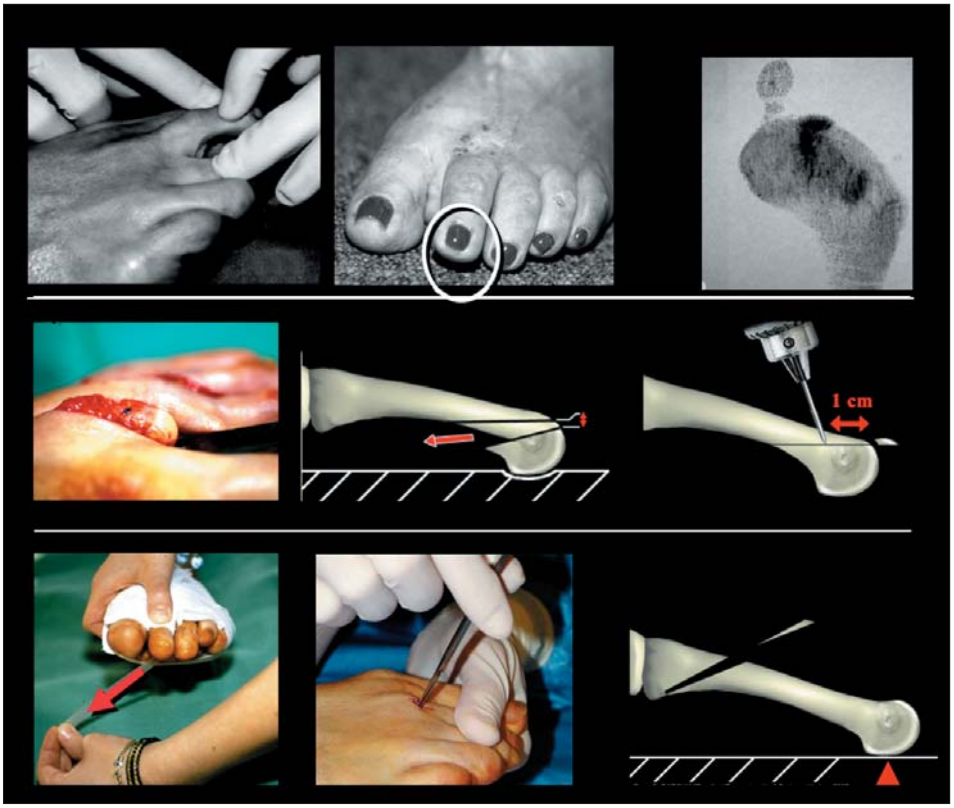


**Fig. 7.** Problems after Weil osteotomy
*Upper line:* the problems: contracture in dorsal flexion, loss of toe ground contact, metatarsalgia remaining
*Middle line:* Preventive solutions: intraoperatively respect of dorsal soft tissues, 2nd layer, Proximal introduction of the screw
*Bottom:* post operatively: plantar toe flexion, if required mini invasive MTP release, BRT osteotomy

In pes cavus with severe metatarsalgia and claw toes, we performed also Weil osteotomy in the first step, followed by the BRT osteotomy one year later

- ***Claw toe***. The Weil osteotomy provides a *longitudinal decompression* (term used by LS Weil). We always remark the decreasing of any claw toe just after the Weil osteotomy. Nevertheless, we reserve the Weil osteotomy in case where *lateral metatarsal are too* long, or in case of *severe* claw toe.

***Transversal deformities:***

- ***Overlapping second toe***. We remark the medial sliding of the metatarsal head as soon as the Weil osteotomy is done. Apart very mild deformities, the Weil osteotomy is necessary and provides reliable results.
- ***Wind swept toes.*** In this case, the lateral shift of the head is observed after the Osteotomy, but it is not sufficient, and a large shortening is required.

**Conclusion**

Weil Osteotomy has to be performed accurately, and its indications are finally *MTP dislocation*, and most of *severe forefoot deformities*, with obviously lateral *metatarsal too long* or *not too long* if the deformity is *very severe.*

**Fig. 8a.** Indications of Weil osteotomy
*Upper line* main indication: MTP dislocation
*Bottom*: severe claw toe, and severe metatarsalgia

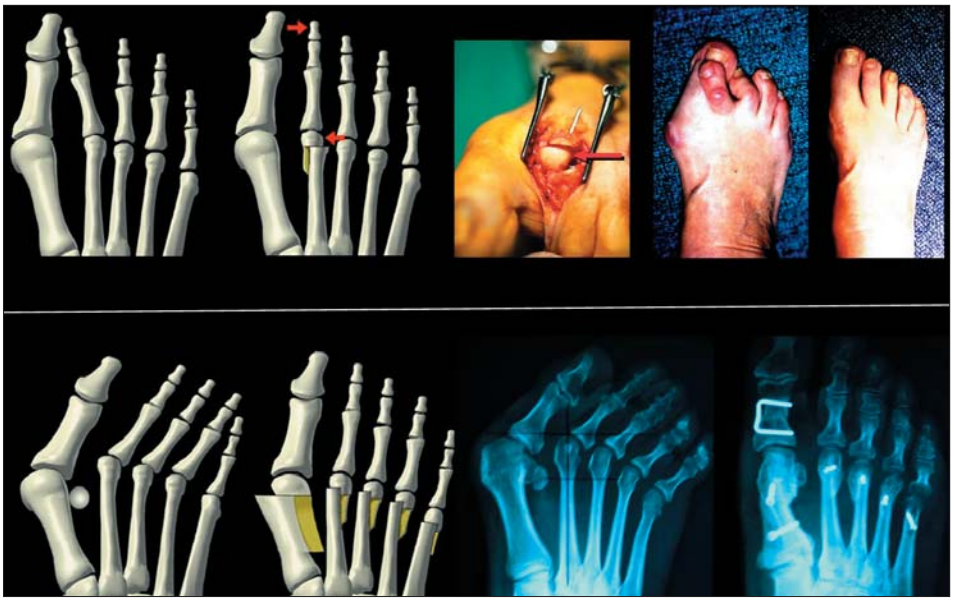

**Fig. 8b.** Indications of Weil osteotomy transversal deviations
*Upper line:* cross over 2nd toe: medial translation of the head (no rotation)
*Bottom:* lateral wind swept. Lateral translation, but above all shortening

## BRT OSTEOTOMY (Barouk, Rippstein, Toullec)

The BRT Osteotomy is a proximal long oblique Osteotomy, performed on the basis of the Metatarsals. It is only an elevation osteotomy.

Some words of the *story*: LS. Barouk, which worked with E. Toullec, met P. Rippstein in 2000, they made already this kind of osteotomy, which seemed to be more accurate and effective than the basal chevron osteotomy: we decide to study this osteotomy, anatomically, technically, and its indications and results.

**Operative technique** (Fig. 9)

Dorsal longitudinal approach is performed for one or several metatarsals

We reach the proximal intermetatarsal edge, which is an important land mark.

1.5 cm from this edge, we begin the cut in a proximal and plantar direction, which follows the proximal curve of the metatarsal. We preserve the proximal and plantar hinge. Fixation with a low profile screw (Barouk or FRS 2.5 diam.),so that there are 2 points ensuring the solidity: the proximal hinge and the screw.

The dorsal wedge removed is slight, because of the long lever arm.

The assessment of the elevation to be done is only clinical, by the palpation of the metatarsal heads. This needs to have prealably removed the plantar callosity.

This assessment is sufficient

The rule is to remove a slight dorsal wedge, This is generally sufficient, but sometimes it is necessary to increase the resection, as far as the palpation of the metatarsal heads reveals that the elevation is sufficient.

To perform too much elevation requires to perform elevation of the neighbour metatarsals.

**Postoperative period**

3 weeks with the heel support shoe are sufficient, because of the solidity of the fixation. Significantly, no MTP stiffness. This is remarkable regarding the other techniques, notably the Weil osteotomy.

**Problems encountred**

In spite of the only clinical assessment of the elevation, the clinical results are reliable. The radiological results are similarly good, but the cut has to be very horizontal and not too much distal. At the contrary, we may observe some cases of healing delay. Hyper or hypo correction are very rare.

**Indications and results** (Fig. 10)

The main Indication is ***metatarsalgia***:

- *sine material,* acquired, isolated in most cases. Very good results are usually observed
- *iatrogenic,* after whatever previous forefoot surgery.

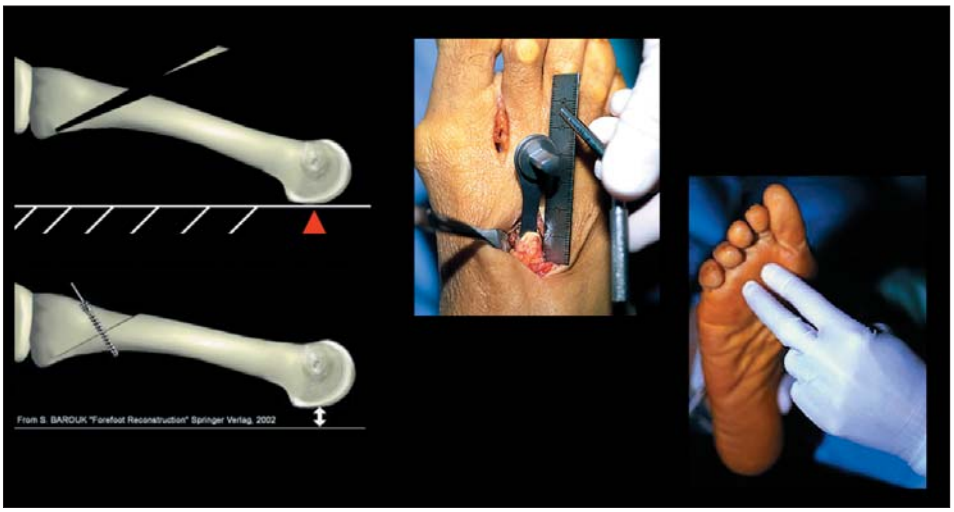


**Fig. 9a.** BRT osteotomy: technique
The dorsal wedge has to be small and the assessment just clinical intra operative

**Fig. 9b.** BRT osteotomy: indications
Metatarsalgia: acquired sine material, iatrogenic. Pes cavus

- Nevertheless, in metatarsalgia, the BRT osteotomy has to be combined if required to claw toe local surgery as well as to gastrocnemius release

Another indication is ***pes cavus***, where the dorsal wedge has to be larger, and the osteotomy mainly performed in the first ray: we associate in most cases the osteotomy of the 2 or 3 first rays. Nevertheless, in case of severe claw toe, we recommend to do a Weil osteotomy first, combined with the claw toe local surgery (see further), then to perform in a second stage the BRT osteotomy.

**Conclusion**

The BRT osteotomy is a basal metatarsal osteotomy, which results only in elevation.

In its indications (metatarsalgia, pes cavus), this Osteotomy provides reliable results, without notable problems encountred. It provides a significant improvement regarding osteotomies usually performed for the same indications, notably the basal chevron osteotomy.

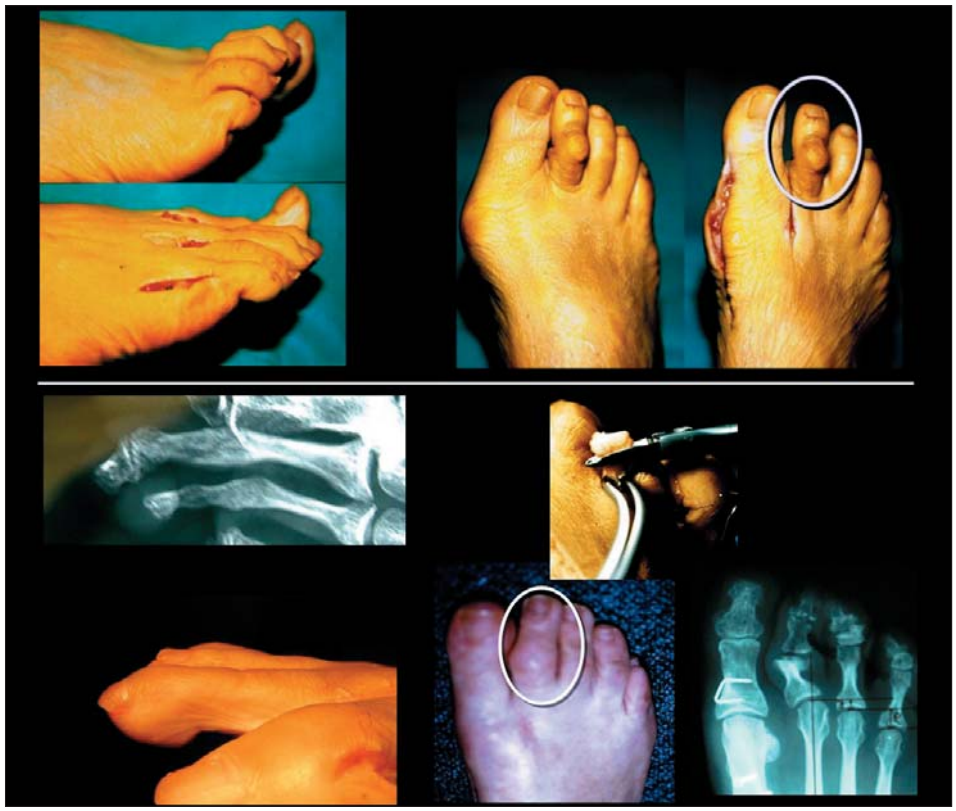

**Fig. 10a.** Claw toe local surgery: introduction
*Upper line:* after Weil osteotomy: improvement of claw toe. After nunionectomy, increasing claw toe
*Bottom, traditional solutions: left:* PIP fusion: unpleasant for the patient, mallet toe. *Right:* PIP arthroplasty: almost only good for the surgeon!

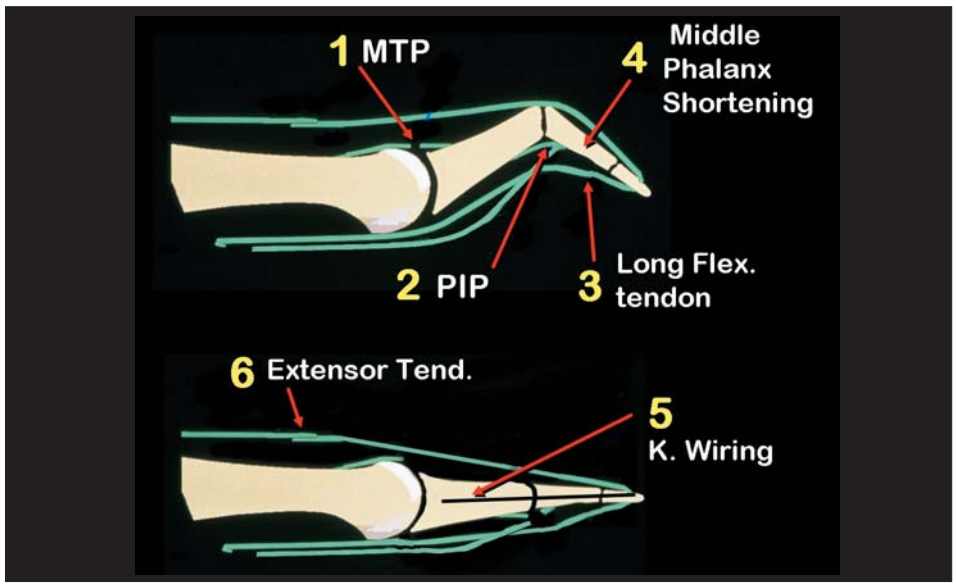


**Fig. 10b.** Claw toe correction: the successive steps for local surgery

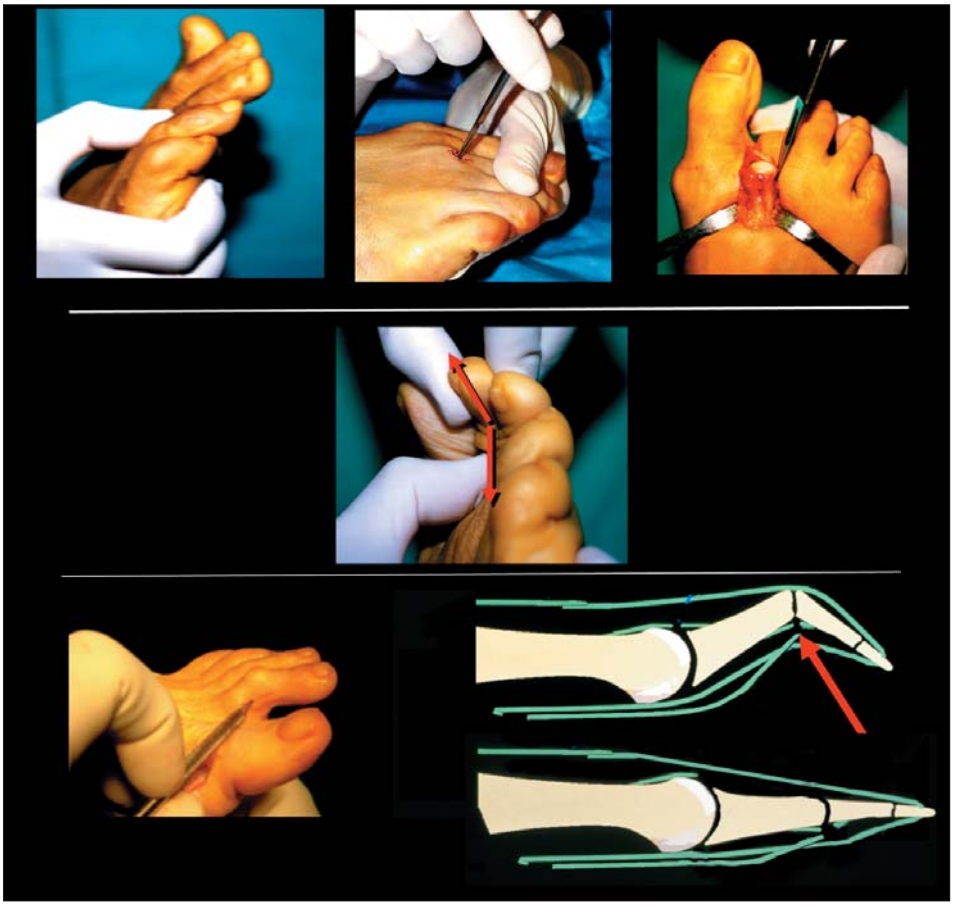

**Fig. 10c.** Claw toe correction: MTP and PIP release
*Upper line:* MTP if required, percutaneous or open MTP release
*Bottom:* PIP manipulation only: 45° of dorsal Flexion is enough. If no effective, make a PIP plantar release: this corrects almost all cases of "fixed" claw toes

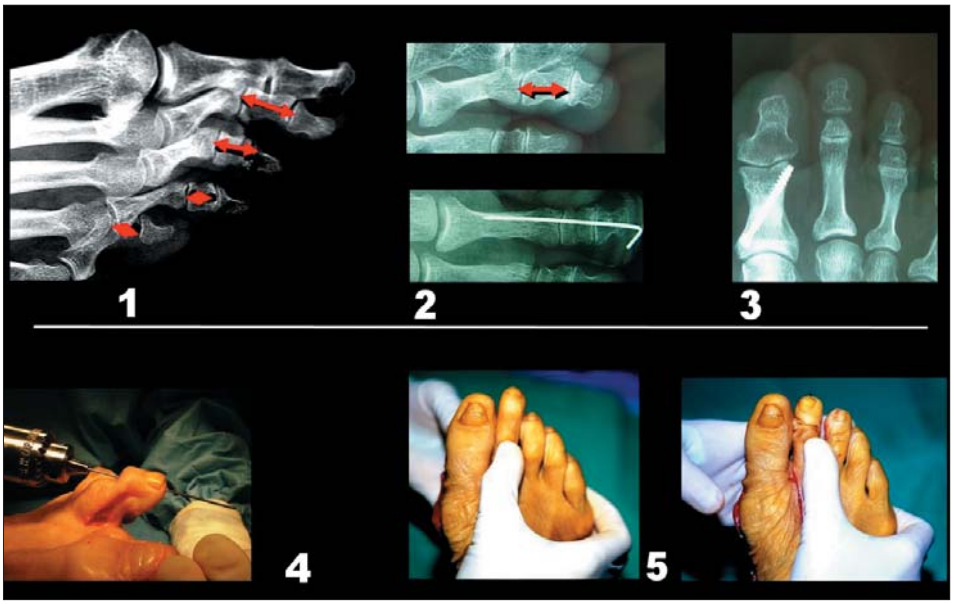


**Fig. 10d.** Claw toe correction: toe shortening
1. Our choice of location: middle phalanx. However, the middle phalanx must be long enough, so this is reserved to the 2nd and 3rd toes (arthroplasty for the 4th and 5th toes). 2. Shortening in the shaft 3. Shortening in the distal part. 4. Easy K wiring 5. Result of this shortening

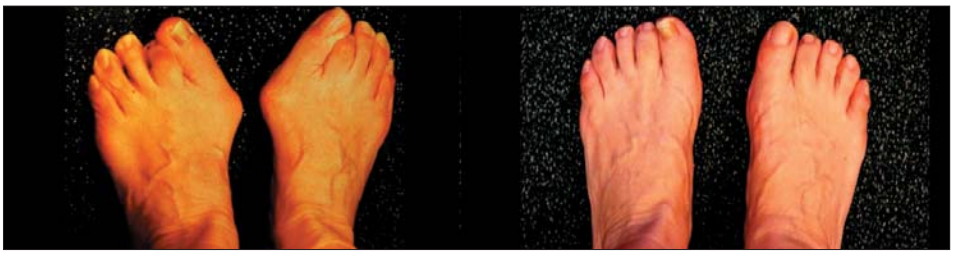

**Fig. 10e.** Claw toe correction: ***Result*** usually observed with this procedure of local claw toe surgery

## CLAW TOE LOCAL SURGERY

Claw toe Local Surgery is indicated in most of Forefoot Surgeries.

The Weil osteotomy can correct a claw toe in some cases, but often not entirely, similarly for the BRT osteotomy.

In bunionectomy, not only the claw toe is not corrected, but the deformity is emphasized

So that a local surgery is often required.

We were not satisfied of the ***usual procedures*** for correction of claw toe deformity: PIP Fusion leaves a not satisfied patient, and it may occur a mallet finger. PIP arthroplasty is really satisfacting for the surgeon, not for the patient!

So that we propose a local surgery which emphasize notably the PIP Plantar release and, if required, a shortening on the middle phalanx level.

**Chronologically**

On the ***MTP,*** a passive plantar flexion has to be obtained, (it may be a percutaneous surgery).

On the ***PIP***, sometimes hyper passive dorsal flexion can be obtained, and this is enough. Sometimes the claw toe seems to be fixed, but in fact the PIP plantar release may correct the claw toe in most cases: we perform a PIP plantar release, by a medial approach, releasing the insertion of the flexor brevis on the middle phalanx basis, and cutting the plantar capsula .

In quite all cases, ***K wiring***, excluding the MTP joint, is set for one month.

Nevertheless, a claw toe deformity may have a recurrence if the toe remains too long. So that we perform the ***toe shortening***, but in the ***middle phalanx*** instead of the proximal.

**Conclusion**

We have exposed our techniques for correction of the lateral rays disorders.

In this article our aim was above all to detail the techniques we use, in order to perform them accurately, to avoid the complications, and to bring precisions on their respective indications.

If we try to have an overview on the respective indications and management, please report on our book "Forefoot Reconstruction".

Basically, and to resume the main indications, if we deal with a ***metatarsalgia*** remaining after bunionectomy, we perform the BRT osteotomy if the metatarsal is not too long, a Weil osteotomy if the metatarsal is too long, or if the claw toe is severe.

If we deal with a ***claw toe***, a local surgery has to be made in most cases, but only if proximal disorders have been corrected.

If there is a ***MTP dislocation***, the Weil osteotomy is the only one reliable indication: but, since we have to respect the ms point, we have to shorten at least two ,or in most cases several metatarsals, often the 5 metatarsal, this occurs in case of advanced dislocation, but also in case of any forefoot severe disorders, which is the third topic we propose to expose.

References


1. *Barouk P. Barouk LS. The Weil osteotomy of the first metatarsal in: Forefoot Reconstruction, Paris-Heidelberg. Springer 2005: 11-114.*
2. *Barouk LS. Hammer and claw toe of the lesser rays. In: Forefoot Reconstruction. 2nd edition: Paris. Springer 2005: 205-214.*
3. *Proceedings of the symposium"Gastrocnemius tightness".Directors Barouk LS, Di Giovanni CH. SFMCP-AFCP French Spring Meeting Toulouse 2006. Med Chir Pied Paris 2006 Springer, 22: 131-158.*
4. *Barouk LS. Use of a postoperative shoe without forefoot support, comparative study. Actualités en medecine et chirurgie du Pied, XVI, 1986: 57-69.*
5. *Barouk LS. The BRT Proximal Metatarsal Osteotomy. In: Forefoot Reconstruction. 2nd edition. Paris Springer 2005: 205-214.*