The role of videothoracoscopy in the diagnostics and surgical treatment for chest trauma

Original article/Artykuł oryginalny © J ORTHOP TRAUMA SURG REL RES 2 (32) 2013

Khadjibaev A.M., Rakhmanov R.O., Isakov Sh.Sh., Dehkanov S.A., Vahidov U.H.

Republican Research Centre of Emergency Medicine, Tashkent, Uzbekistan

Address for correspondence/ Adres do korespondencji:
Republican Research Centre of Emergency Medicine, 100107, Uzbekistan, Tashkent, Farhadskaya-2
Tel. (998 71) 279-34-95
Cell phone: (998 90) 911-3-911
Fax: (998 71) 150-46-05
e-mail: dr_rro@mail.ru

Received: 24.04.2012
Accepted: 05.06.2012
Published: 31.05.2013

STATISTIC STATYSTYKA	
Word count Liczba słów	1729
Tables Tabele	6
Figures Ryciny	6
References Piśmiennictwo	19

Summary

Background. The results of investigation and treatment of 1396 patients with blunt chest trauma (952 patients, 68.2%) and chest injury (444 patients, 31.8%) had been analyzed.

Materials and methods. The first group consists 552 (39.5%) patients with management without the video-assisted thoracoscopic surgery (VATS), the second one includes 844 (60.5%) patients with VATS. Gender determination: male 1192 (85,4%), and female 204 (14.6%), aged 17-83 years (average 42.5±2.1). Pleural cavity puncture (128 patients), pleural cavity draining (400 patients) and primary wide thoracotomy (24 patients) were used in the 1st group of patients with traditional surgery approach. In the 2nd group of patients in 40 (4.7%) cases of VATS the conversions to wide thoracotomy had been made due faced technically difficulties during the primary VATS technique.

Results. Postoperative complications occurred in 92 (10.9%) patients group 2 and in 140 (25.4%) patients, who underwent the traditional approach. The postoperative complications were eliminated by thoracotomy in 28 (5.1%) patients of the 1st group and in 4 patients (0.5%) of the 2nd group. VATS has decreased the frequency of thoracotomy in 5.2% (44 of 844 patients), meanwhile in the traditional approach the thoracotomy has been made in 9.4% cases (52 of 552 patients).

Conclusions. Thus, VATS allows not only to establish exact topical diagnosis, but also to quickly and reliably eliminate damages avoiding open intervention with the minimum trauma for the patients.

Key words: chest trauma, diagnostics, treatment, video-assisted thoracoscopic surgery (VATS)

BACKGROUND

The injury rate has become one of the important medico-social problems in industrialized countries that require huge financial expenditure to solve them. [3, 8]. Chest traumas take the third place after cripples and craniocerebral trauma making 30-40% of hospital admissions, at that some 90% of the injured are able-bodied population.[1, 10, 11, 15, 17, 18]. Chest injury (CI) is run by continuous care and rehabilitation, large quantity of suppurative-septic complications (up to 20%) and high fatal outcomes (from 17 to 30 %) [6, 5, 7, 9, 14, 16].

According to analysis, 15% of patients died after CI had no fatal injuries and they died from defects of medical help. As a rule, injury late diagnostics stipulated inadequacy of primary aid [2, 12, 13, 19]. Poor resolution of simple X-ray of thorax in thoracic injury does not allow estimating the condition of the injured on admission and during the treatment that further results in wrong therapeutic approach [4, 18]. CI diagnostic difficulties lead to unreasonably continuous follow-up, to carry out conservative therapy if urgent surgery is needed. In these cases retention in the selection of correct surgical approach usually results in the development of severe complications and increase in fatal outcomes. Herewith, the frequency of unreasonable thoracotomy ranged from 10 to 15% [13]. In the light of the above-mentioned the urgency of tasks on further CI diagnostics and treatment became obvious.

AIM OF THE WORK

The aim of present work is to improve the results of CI surgery by early and wide use of medical-diagnostical facilities of videothoracoscopy (VATS).

MATERIAL AND METHODS

There analyzed the findings of examination and surgery cases of 1396 patients with blunt chest trauma (BCT) and chest injury. I group included 552 (39,5%) patients who had been made examination and traditional treatment without VATS. II group were 844 (60,5%) patients who underwent VATS during primary diagnostics and surgery. There were male 1192 (85,4%) and female 204 (14,6%) aged between 17 to 83 years. Half of the injured (51,9%) was admitted within first 6 hours. Of 1396 patients 444 (31,8%) had penetrating stub-cut CI and 952 (68,2%) patients had.

We observed that BCT had frequent similar localization on the right and left sides (43,7% and 50,8% correspondingly) and CI prevailed on left side in 304 (68,5%) patients.

Combined character of injuries occurred in 152 (27,5%) patients of 1 group of patients and in 204 patients (24,2%) of II group of patients. CI combined more often with craniocerebral traumas and fractures of extremities.

Complex methods of CI patient examination, in addition to general clinical examination, included laboratory (CBC and urine analysis), noninvasive (US and X-ray examination of thorax) and invasive (puncture and pleural cavity draining) methods of investigation as well as VATS (in II group of patients).

CI general clinical manifestations were as following: chest pain in 1352 (96,8%) patients, short breath in 964 (69,1%) patients and common fatigue in 1248 (89,4%) patients. It should be noted that every fourth injured patient of 376 (26,4 %) patients had a sign of lung tissue damage - blood spitting.

To follow representativeness of comparative groups our research did not include patients with critical conditions and patients with unstable hemodynamics after infusion-transfusion therapy whereas VATS was contraindicated to those patients.

X-ray of thorax revealed different pathological changes in 1304 (93,4%) patients. Thus, hemothorax (HT) was determined in 240 (17,2 %) patients, pneumothorax(PT) was in 360 (25,8%) patients, haemopneumothorax (HPT)

Tab. 1. Character of intrapleural injuries diagnosed within VATS in closed thoracic injury. N=452

Intrapleural injuries	Number of patients	
	absolute	%
Subpleural bleeding and hematoma of chest wall	452	100
Ruptures of parietal pleura	444	98,2
Lung lacerations	408	90,3
Lung bulla lacerations	8	1,8
Lung contusion	60	13,3
Intraparenchymal hematoma	32	7,1
Mediastinal hematoma	4	0,9
Ruptures of mediastinal pleura	12	2,7
Pneumomediastinum	32	7,1
Rupture of diaphragm	8	1,8
Hemothorax	372	82,3
Intrapleural bleeding from:		
• Muscular vessels	44	9,7
• Intercostal vessels	8	1,8
• Lung lacerations	60	13,3
• Elbow fractures parts	12	2,7
• Small vessels of mediastinum	12	2,7
• Raptures of diaphragm	4	0,9

in 768 (55,0%), subcutaneous emphysema of thorax- in 684 (49%), lung contusion – in 36 (2,6%), heart shadow dilatation - in 28 patients (2%) and pneumomediastinum - in 28 (2%) patients. Single elbow fracture was diagnosed in 208 (21,9%) patients of 1 group of patients and in 84 patients (18,6%) of 2 group of patients. Multiple fractures were found in 328 (68,9%) patients of 1 group of patients and in 328 (72,6%) of 2 group of patients ($p > 0,05$).

USD of thorax and abdominal cavity were performed on 1284 (92%) patients. The main task of sonography at thoracic traumas was to detect hemothorax which was diagnosed in 884 (68,8%) cases. USD was not informative due to subcutaneous emphysema of thorax in 104 (8,1%) examined patients. Meanwhile, USD allowed to identify changes on the side of abdominal cavity in 304 (23,7%) patients with combined trauma.

In 2 group of patients it was added VATS to abovementioned list of instrumental investigations (844 injured patients). Indications to VATS were HPT in 540 (64%), HT in 160 (19%), PT in 124 (14,7%), isolated subcutaneous emphysema without HPT signs in 12 (1,4%), dilated heart borders in 8 (0,9%) patients.

We were able to reveal all of the most probable variants of injuries of chest wall, pleural leaves, mediastinum and lungs throughout endoscopic revision of pleural cavity in injured patients with closed thoracic injury (Table 1). It has been determined, that closed trauma certainly combines with subpleural hematomas in elbow fractures (452 patients) and parietal pleura disruptions always take place there (444 patients). In all cases, when hemopneumothorax, pneumothorax as well as subcutaneous emphysema were indicated for VATS, we determined lung lacerations (408 patients) or bullas (8 patients).

The value of VATS increases more in penetrating TI, as the probability of heart and diaphragm damage, reliable diagnostics of which is barely difficult with traditional endovisualization facilities, is much higher than in CTI. Thus, we revealed diaphragm injures in every fourth thoracic injured patient, who underwent videoendoscopy (Table 2). In 8 cases, when clinical, X-ray, US signs were absent, VATS allowed to determine that severe complication of trauma. It should be noted that we have done no single misdiagnosing in VATS group.

RESULTS AND DISCUSSION

Pleural cavity puncture (128 patients), pleural cavity draining (400 patients) and primary wide thoracotomy (24 patients) were used in I group of patients with traditional surgery approach (Table 3). Small hemothorax or wall pneumothorax up to 1/3 of lung volume was an indication for making thoracocentesis to the injured. Besides, the absence of multiple injuries and localization of injury in “safe zones”: out of “cardiac” and “thoracoabdominal” zones are compulsory condition to thoracocentesis in thoracic injuries. About half of patients (56 (43,8%)) underwent to thoracocentesis we were not able to get expected result, therefore we had to perform pleural cavity draining in 48 (37,5%) cases and in 8 (6,3%) patients – wide thoracotomy as well. In recent years we have declined punction way of treatment in thoracic injury complications.

In two groups primary wide thoracotomy provided with adequate extensive surgical approach for reliable elimination of all revealed consequences of thoracic traumas, but nevertheless, predisposing thoracoscopic revision of pleural cavity allowed to avoid unnecessary thoracotomy. In II group of patients in all 40 cases of VATS conversions to wide thoracotomy were made manipulations which are technically difficult to carry out with endoscopic technique (suturing of lung ruptures – 12, IVC injuries – 4, heart – 8, pericardiotomy and revision of heart on pericardial injury – 16). Meanwhile, in I group

Tab. 2. Character of intrapleural injures determined in patients with thoracic injures within VATS. N=392

Intrapleural injuries	Number of patients	
	absolute	%
Parawound subpleural haematomas	132	33,7
Elbow and cartilage cut	20	5,1
Lung injure	156	39,8
Intraparenchyme hematomas and subpleural bleeding of lung	20	5,1
Wound and hematomas of mediastinum	8	2,0
Pericardial injure	24	6,1
IVC	4	1,0
Heart injure	8	2,0
Diaphragmal injures	92	23,5
Haemathorax	288	73,5
Intrapleural bleeding from:		
• Muscular vessels	76	19,4
• Intercostal vessels	24	6,1
• Internal thoracic artery	8	2,0
• Lung injuries	60	15,3
• IVC	4	1,0
• Pericardial injuries and heart	12	3,1
• Injury of diaphragm	52	13,3

of patients we had to evacuate retained hemotorax in 24 primary and 28 secondary thoracotomy in 12 cases, and in 12 cases - suturing of superficial lung injury (8) and rupture of lung bulla. All mentioned procedures could be performed on VATS.

In second group of patients of 152 cases VATS conversion we could restricted by VATS-manipulations via minithoracotomy approach using the same thoracoscopic technique in 112 cases. Adequate endoscopic revision and assessment of intrapleural situation allowed selecting optimal surgical approach and decreasing the frequency of reoperations in 0.5% versus 17.4% in traditional surgical approach group (Table 3).

In addition to high diagnostical effect of VATS, our method differs with quite wide medical opportunities (table 4 and fig.1-6). This provided to decrease frequen-

Tab. 3. Results of primary surgical treatment

Character of primary intervention		Number of patients	Recurrent interventions	
			Character	Quantity
I group	Pleural cavity puncture	128	Drainage Thoracotomy Total	48 (37,5%) 8 (6,3%) 56 (43,8%)
	Draining of pleural cavity	400	Redraining Thoracotomy VATS Total	8 (2%) 20 (5%) 12 (3%) 40 (10%)
	Thoracotomy	24		
	Total	**552**		**96 (17,4%)**
II group	VATS	804	Thoracotomy	4 (0,6%)
	VATS+thoracotomy	40		
	Total	**844**		**4 (0,5%)**

Tab. 4. Character medical procedures within VATS in thoracic injuries

Medical procedure	Number of patients	
	absolute	%
Pleural cavity sanation	792	93,8
Haemothorax evacuation	452	53,6
Bleeding control from:	240	28,4
– muscular vessels	120	14,2
– intercostals ěÍćđÍáÍđíűő ńîńóäîâ	24	2,8
– internal thoracic artery	4	0,5
– injury of lung	52	6,2
– small vessels of mediastinum	12	1,4
– bone fracture of elbows	12	1,4
– injury of diaphragm	16	1,9
Suturing of lung injury	84	10,0
Incision of mediastinal pleura	20	2,4
suturing of diaphragmal injury	8	0,9
Suturing of lung injury	4	0,5
Coagulation of bullas' rupture	4	0,5

Tab. 5. Character of postoperative complications

Type of complications	I group, n=552		II group, n=844	
	absolute	%	absolute	%
Unspecific complications	40	7,2	44	5,2
• *Postoperative pneumonia*	40	7,2	44	5,2
Specific complications	100	18,1	48	5,7
• *Wound infection*	*8*	*1,4*	*8*	*0,9*
• *Ongoing pneumothorax*	*56*	*10,1*	-	-
• *Retained hemothorax*	*4*	*0,7*	-	-
• *Exudative pleuritis*	*24*	*4,3*	*36*	*4,3*
• *Lung atelectasis*	*4*	*0,7*		
• *Intrapleural bleeding*	*4*	*0,7*	*4*	*0,5*
Total:	**140**	**25,4**	**92**	**10,9**

cy in 4.7% (table 3), whereas in traditional approach primary (24) and secondary (28) thoracotomies were made in 9.4% cases (in 52 of 552 patients).

Clinical experience, skills and assurance gained during this investigation in using of treatment-diagnostic opportunities of VATS allowed us to implement endoscopic technique much wider in combined traumas and abdominal injury. In second group of patients those injured were 148 (17,5%) patients. Usually, laparoscopy was performed at the second stage after VATS. At this stage of laparoscopy implementation in abdominal traumas we tried to restrict indications for diagnostic lapa-



Fig. 1. VATS. Mediastinal pleura cutting

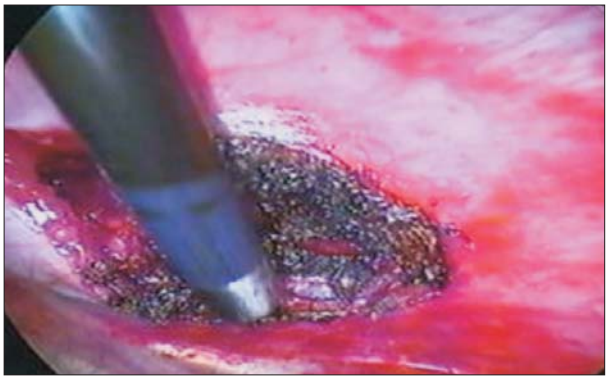

Fig. 2. VATS. Coagulation of injury of parietal pleura

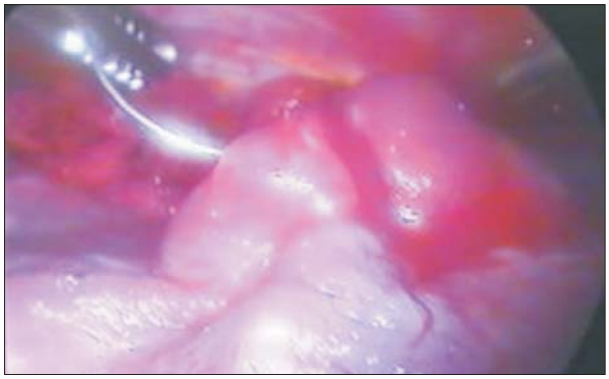

Fig. 3. VATS. Lung injury suturing

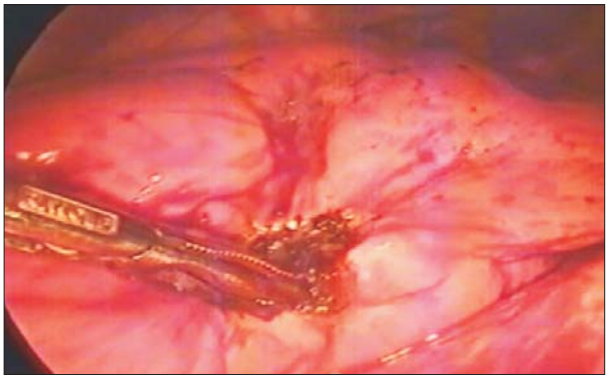

Fig. 4. VATS. Coagulation of lung injury

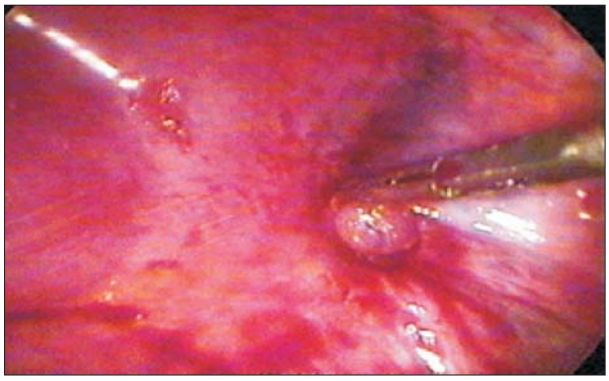

Fig. 5. VATS. Coagulation of diaphragm injury

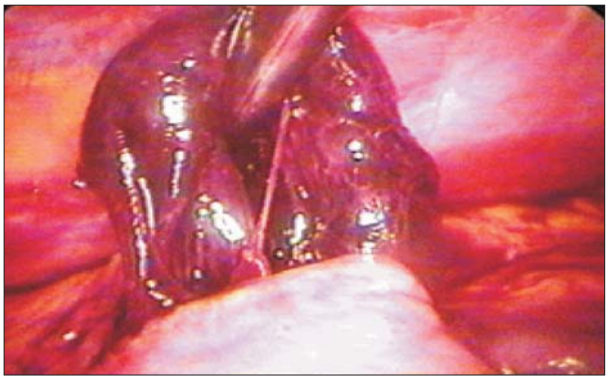

Fig. 6. VATS. Elimination of retained hemothorax

Tab. 6. Results of traditional methods for patients' treatment

Indication	I group, n=552	II group, n=844	P
Frequency of thoracotomy, %	9,4	5,2	χ^2=7,12; p<0,05
Duration of pleural draining, days	4,6±0,31	2,2±0,32	t=5,56; p<0,05
Common frequency of complications, %	25,4%	10,9%	χ^2=8,51; p<0,05
Durations of in-patient treatment, days	8,1±0,36	7,1±0,27	t=2,22; p<0,05

roscopy by two situations: 1) injuries (80) or ruptures of diaphragm (4) revealed within VATS; 2) combined injuries of upper abdominal wall (4) and clinical-sonographic sings of abdominal organs (60).

In 52 (35,1%) cases using endoscopic technique we could avoid laparotomy: we excluded the damage of abdominal organs in 40 patients and we performed endoscopic hemostasis successfully in 12 patients with superficial liver injury. We considered purposeful and more trustful to use wide surgical approach in rest of cases.

Therefore, VATS allowed us to eliminate intrapleural complications of trauma in 312 (37%) patients, excluding routine aspirations of effused blood. Postoperative complications occurred in 92 (10,9%) patients of II group and in 140 (25,4%) patients who underwent traditional approach (Table 5).

Most of postoperative complications were eliminated conservatively or by the means of minor surgery (by pleural punctures and pleural cavity draining). Secondary surgeries such as thoracotomy were made to 28 (5.1%) patients of I ("traditional") group and 4 (0.5%) patient of II group (see table 3).

In comparison with traditional methods advantages of VATS in thoracic injury are also testified by data, shown in table 6, where the differences in two groups have statistically justified character by the frequency of thoracotomy, duration of operative interventions and draining of pleural cavity, complications of traumatic disease in early period.

None of patients had fatal outcome.

Thus, VATS prevails the other noninvasive and minimally invasive methods of thoracic injury diagnostics. In difference to these methods, VATS allows not only to make accurate diagnosis, but also to eliminate injuries, which are not required open intervention with minimal trauma to the injured.

CONCLUSIONS

To apply videothoracoscopy allows performing full-fledged look and diagnosing of injury of thoracic cavity and mediastinum organs, bleeding control, hermetic ruptures of lungs, sanation and draining of pleural cavity. The use of videothoracoscopy enhances diagnostic process, lessens duration of pleural cavity draining in postoperative period, provides early activation of patients, and reduces treatment and rehabilitation time. Videothoracoscopy is to become a part of algorithm of diagnostic and medical procedures in thoracic injury. Surgical approach of treatment for thoracic injury needs to be determined not by the results of primary draining of pleural cavity but by results of thoracoscopic revision considering medical opportunities of videoendoscopic technique.

References/Piśmiennictwo:

1. *Abakumov M.M., Lebedev N.V., Makarchuk V.I. Objective assessment of trauma severity in injured patients with combined injuries.// Surg.vestn. 2001:160: Nº 6: 42–45.*
2. *Bisenkov L.N, Kochegarov O.V. Diagnosing and treatment of heart injury. // Thoracic and cardiovascular surgery.1999: Nº 2: 39-43.*
3. *Borisov A.E., Mitin S.E., Chlopov V.B. et al. Endovideosurgery opportunities at treatment of chest trauma// Endoscopic surgery. 2001: Nº 3: 32.*
4. *Brusov P.G., Kuricin A.N., Urazovski N.Yu. et al. Operative videothoracoscopy at surgical treatment of bullet penetrating thoracic trauma at medical evacuation stages on local military conflict. // Endoscopic surgery. 1998: Nº 3: 10-14.*
5. *Dobrovolski S.R. Treatment of chest trauma//Surgery.2007: Nº 5: 32-38.*
6. *Ermolov A.S., Abakumov A.V., Pogodina A.N. et al. Diagnostics and treatment of posttraumatic retained haemotorax//Surgery. 2002: Nº 10: 4-9.*
7. *Karimov Sh.I, Krotov N.F., Shoumarov Z.F. et al. The first experience of videothoracoscopic operation at various surgical pathology.//Surgery of Uzbekistan. 1999: Nº 3: 78-80.*
8. *Kochergaev O.V. Diagnostic features of direct lung injuries on combined chest traumas. // Thoracic and cardiovascular surgery. 2002: Nº 1: 48-52.*
9. *Krotov N.F., Ganiev Sh.A., Berkinov U.B. et al. The role of videothoracoscopy in diagnosing and treatment of chest trauma. // Surgery of Uzbekistan. 2006: Nº 3: 62-63.*
10. *Ismailov D.A., Tashbaev A.M., Kurbanov S. Qualified surgical aid on chest trauma// Surgery of Uzbekistan. 2000: Nº 3: 43-44.*
11. *Porhanov V.A., Polyakov V.B., Kononenko V.B. et al. Videothoracoscopy in treatment of patients with traumatic injuries of chest//Annals of surgery.2001: Nº 2: 44-50.*
12. *Florikyan A.K. Surgery of chest trauma. (Pathophysiology, clinical features, diagnostics, treatment) – Charkov: Osnova. 1998:509.*
13. *Sharipov I.A. Chest trauma (problems and release). 2003:328.*
14. *Ahmed N., Jones D. Video-assisted thoracic surgery: state of the art in trauma care // Int. J. Care Injured. 2004: Vol. 35: 479-489.*
15. *Carrillo E.H., Kozloff M., Saridakis A. et al.Thoracoscopic application of a topical sealant for the management of persistent posttraumatic pneumothorax / // J.Trauma.2006:Vol. 60: Nº 1: 111-114.*
16. *Chan L., Reilly K.M., Henderson C. et al. Complication rates of tube thoracostomy // Amer.J.Emerg.Med. 1997: Vol.15: Nº 4: 368-370.*
17. *Esme H., Solak O., Yurumez Y. et al. The prognostic importance of trauma scoring systems for blunt thoracic trauma / // Thorac.Cardiovasc.Surg. 2007: Vol. 55: 190-195.*
18. *Gavelli G., Canini R., Bertaccini P. et al.Traumatic injuries: imaging of thoracic injuries // Europ.Radiol. 2002: Vol. 12: 1273-1294.*
19. *Villavicencio R.T., Aucar J.A., Wall M.J. Analysis of thoracoscopy in trauma // Surg Endosc. 1999: Vol. 13: Nº 1: 3-9.*