# VEPTR. Thoracic Insufficiency Syndrome and Exotic Scoliosis

R. RIISE
National Hospital, Norway

VEPTR (vertical expandable prosthetic titanium rib) was invented by Dr Campbell, St Antonio, Texas in 1989. The concept of VEPTR was developed for treating a patient with thoracic insufficiency syndrome. The implant went through several developments until 1995. Since then the construction has not gone through any major changes. The VEPTR was approved by FDA 2004.

The thoracic insufficiency syndrome (TIS) is characterized as the inability of the thorax to support lung growth or respiration due to severe malformation of chest, spine or ribs, small thoracic volumes, inadequate lung development, thoracic stiffness or iatrogenic.

It is important to emphasize VEPTR is used on children in order to support the growing lungs, and has not been used on adults.

The main indication for VEPTR is congenital scoliosis with fused ribs, absent ribs and scoliosis, foreshortened thorax and transverse constricted thorax.

The indications have broadened over the years. There are several reports in the literature presenting MMC and neuromuscular cases/series.

The implant is cranially attached on the ribs, caudally it can be attached on ribs, lumbar lamina, iliac crest or a combination of either. VEPTR aim a 3 dimensional reconstruction of the chest. Indirectly it will correct some of the scoliosis as measured with Cobbs method. Other, and more important success criteria are Space available for lung, Posterior hemithorax symmetry ratio etc.

After application the patient has to undergo expansion procedure every 4-8 months in order to keep up with the growth of the child.

Infantil and juvenil (early onset) idiopathic scoliosis usually requiring treatment when the curve >30/35 degrees measured with Cobbs method and showing progression of more than 5 degrees in series and RVAD (rib vertebral angle difference) >20 degrees. This is reckoned by many spine surgeons as a scoliosis requiring treatment. It is important to emphasize the high incidence of spontaneous correction of scoliosis of these patients.

When observations show definite progression most treating surgeons would recommend casting. Type of casting, time in cast and success criteria is still debatable.

Indication and methods for operating treatment is of even greater controversy.

The methods vary from correction and fusion of spine (with or without implant), growing rods, Luque Trolley, SHILLA, staples and VEPTR.

# Surgical management of flexion-distraction dislocation of cervical spine: anterior versus combined posterior-anterior approach

A. MACIEJCZAK, P. BARNAŚ, P. DUDZIAK, B. JAGIEŁŁO-BAJER, B. LITWORA, M. SUMARA

Dr hab. n med. Andrzej Maciejczak
Oddział Neurochirurgii, Szpital Wojewódzki, 33-100 Tarnów, Lwowska 178a

Lesions of flexion-distraction type are characterized by few features, which implement and force certain therapeutic procedures:

1. destruction involves ligaments-and-disc apparatus. Eventual, if ever bony lesions are minimal and affect posterior parts of the vertebra (usually a fracture or abruption of either articular processes or vertebral arches occurs).
2. in the trauma both anterior dislocation and bolting of articular processes are present. Bolting, as seen in the Picture 1. refers to as luxation of the articular process due to swiping of the inferior articular process of the higher vertebra above and anterior the superior articular process of the inferior vertebra. Depending on the extent of flexion-distraction lesions, i.e. uni- or bilateral bolt and its size, the dislocation is graded in a four-grade scale.

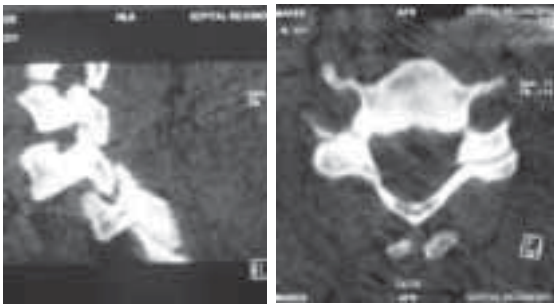

**Picture 1.** Left articular procceses bolted. Axial and transverse reconstruction on C5-C6 level. Authors original radiograms.

**Picture 2A and B.** Complete non surgical preoperative reduction before the surgery. Operation performed via anterior approach. Authors original radiograms.

The mentioned features of flexion-distraction dislocations determine therapeutic procedures:

1. lesion of either ligament or ligaments-and-disc apparatus is an indication for surgical treatment. Arthrodesis, i.e. bone regrowth of the affected segment is an objective. Performance of the anterior intervertebral arthrodesis is then indisputable. Need for accessory posterior arthrodesis is still discussed.
2. the luxation requires its repositioning or reduction. Method of reduction of dislocation produces controversy and discussion between experts. Choice of optimal surgical approach - whether anterior, posterior or if combined in what sequence, is a matter of disputation for a complete treatment of the dislocation.

Experts' opinions can be classified as follows:

1. Anterior only approach. According to some findings is insufficient for complete healing.
   - Each luxation which cannot be reset conservatively, i.e. non-surgically can be reduced in this method. Intraoperative distraction of the vertebral bodies is effective in reduction according to these authors.
   - Anterior arthrodesis is sufficient, in their opinion, even in high grade dislocations, where both columns instability of the vertebral column is present.
2. Combined posterior-anterior approach. In most authors' opinions high grade dislocations require both anterior and posterior approach. They argument their statement:
   - The articular processes can be unbolted via a posterior approach always, when non-surgical reduction (traction, manipulation) fails. For complete healing additional anterior stabilization and arthrodesis is required. The question is, wheather to perform these approaches in one step or in a delayed sequence.
   - High grade lesions destabilize both columns of the spine, so both need to be stabilized and require arthrodesis. The sequence (anterior-to-posterior or opposite) may be discussed or depended on preoperative reduction of luxation.

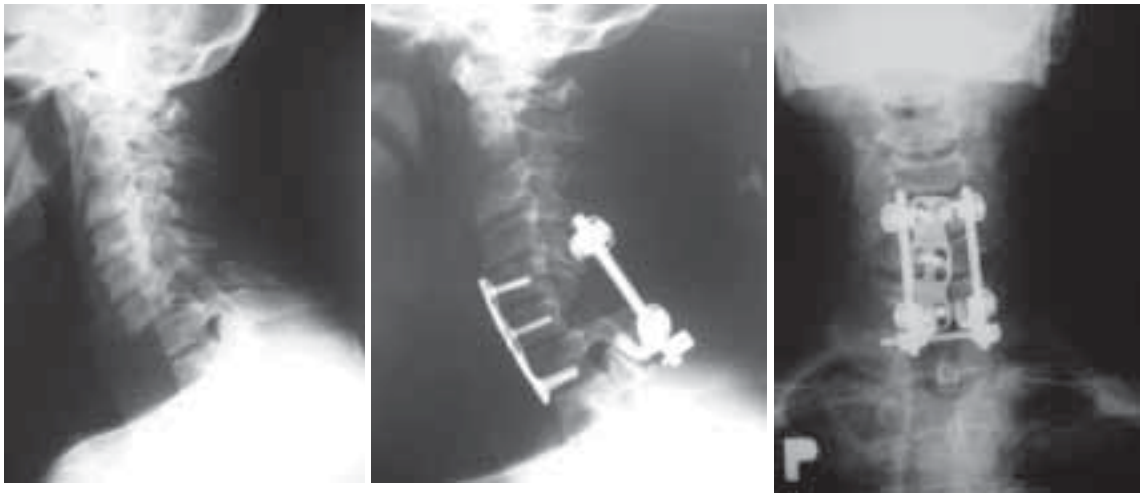

**Picture 3A, B, C.** A single step posterior and anterior surgical repair of the flexion-distorsion cervical spine trauma. Authors original radiograms.

Perennial experiences of the first author of this paper in treatment of flexion-distortion trauma of the cervical vertebral column resulted in creation of an algorithm. The therapeutic regime proposed in this algorithm is clinically applicable and was successfully implemented in neurosurgical ward in Tarnow, Poland.

1. Under general anesthesia, in complete muscular relaxation patient is laid in a dorsal horizontal (i.e. recumbent) position. A manipulation is performed under C-arm. If the reduction is effective the subsequent operation is performed through anterior access only. Anterior vertebral arthrodesis and stabilization are then performed.
2. If manual reduction fails a surgical one is performed through posterior approach. Patient is laid laterally or in ventral horizontal position for this purpose. Vertebral column is then exposed for a direct surgical unbolting of the processes. When proper repositioning is reached, it becomes secured by a posterior arthrodesis and stabilization. The wound is sutured and patient is secondarily inverted to recumbent position for anterior vertebral stabilization and arthrodesis.
3. In rare cases, when even direct reduction fails, patient should be laid in recumbent position and anterior cervical corpectomy of the inferior vertebra in the dislocation can be done. It is also a choice for anterior only approach, when posterior one is not planned.

# Computer Assistance in Spine Surgery: Is it of any benefit?

D. SCHLENZKA
ORTON Orthopaedic Hospital, Helsinki/Finland

Stereotactic principles, used primarily for brain surgery, have been developed further and introduced into spine surgery at the beginning of the last decade.

Lumbar pedicle screw insertion was the first clinical application for this technique.

The effectiveness of this new technique has been shown in prospective studies (Schwarzenbach et al 1997, Laine et al 1997, 2000). In those studies the rate of minimal perforations of the pedicle cortex in the lower thoracic and lumbar region was less than 5 per cent, i.e. significantly lower if compared to conventional srew application techniques.

Despite of this clear evidence, navigation systems are used routinously for spine surgery only by a few enthusiasts. The most common justifications not to use this technique are:

- "I don't need it ."
- "It is time consuming."
- "It is unreliable (inaccurate)"
- "It is expensive."

This critisim is usually expressed by surgeons who have only limited (but frustrating) experience with navigation or no practical experience at all.

It is true that the majority of misplaced pedicle screws do not cause neurologic symptoms. This gives the surgeon a wrong impression of his or her performance. It creates a sense of safety and the feeling that there would be no need for improvement. Acknowledging the high rate of pontentially dangerous misplaced screws, it is very difficult to understand why one should not utilise every possible means to minimise the danger of causing damage to the patient. The single unlucky patient with a permanent nerve lesion will not take comfort in the fact that his or her problem occurs only in a very small percentage of cases. For this patient the catastrophy is complete - 100 per cent.

Time is an important issue. Navigation takes time for preoperative planning as well as intraoperatively, especially during the learning phase. After the surgeon has become used to the technique the extra time needed is minimal. In cases with severely distorted anatomy (deformities, reoperations), navigation saves time because orientation becomes much easier during the operation. In addition, the radiation exposure of the theatre staff is reduced markedly. The time invested in preoperative planning is never wasted. In our experience it gives one a deeper understanding of the patient's individual anatomy.

Judging the accuracy of navigation one has to understand thoroughly the underlying technique which includes several steps with a certain degree of technically unavoidable imprecision. The practical accuracy of a ct-based optoelectronic navigation system under clinical conditions is around two millimetres. That means if the diameter of the target is less than four millimetres one approaches the limits of the system. The producers of navigation systems are usually not able to present reliable data

on system accuracy. Therefore it is very important to test the accuracy of a navigation system under clinical conditions before purchasing it and taking it into routine use.

Navigation systems are (still) very expensive. Simpler technical solutions may reduce their price in the furture. Our decision depends also very much on how much we are willing (or able) to invest in order to avoid complications which may be much more costly.

After more than ten years of positive practical experience with navigation, the author is convinced that navigation will finally make its breakthrough in spine surgery for the benefit of our patients.

## Posterior kyphectomy as an operative treatment of kyphotic deformity in myelomeningocoele

B. BAKALAREK
Clinic of Juvenile and Adolescent Orthopedics and Rehabilitation,
Collegium Medicum of Jagiellonian University in Zakopane
Head of Clinic: professor Daniel Zakrzycki MD, PhD

A group of 51 patients was operated on for major kyphotic deformities accompanying myelomeningocoele. All of the group suffered from disraphic disturbances in the inferior thoracic and lumbosacral part of the vertebral column. They presented a complete paraplegy with a typical "sitting Budda" position. Mean angle of the lumbar kyphosis before the operation was 145°, ranging from 117° to 181°. The deformation was characterized by a short and sharp curve, being minimally corrective. Such a malformation compressed the thoracic and abdominal viscera thus affecting physical development of these children. Operative technique in all cases was correction of kyphosis through vertebrectomy on the peak of the hump via a posterior access. A subsequent correction with Luque rods and stabilization posterior to the sacrum was performed. In order to avoid complications like great vessels tear due to over-correction 2-3 lumbar vertebrae were totally excised in every case. The kyphoses were minimized of average 79° (57°-95°) during the operation; operative correction reached 59% (48%-72%). A significant improvement in sitting comfort and decompression of the viscera were reached.

Noted complications included 1 case of sepsis, transient circulatory disorder in the inferior extremity in another case. Significant loss – 49% of correction was observed in one patient resulting from rods ploughing in the sacrum; a refractory cerebrospinal fluid outflow was seen in 1 girl. 6 patients suffered from impaired wound healing caused by bad preoperative condition of the skin.

## Radiofrequency denervation for chronic mechanical low back pain

J. DOBROGOWSKI
Department of Pain Research and Therapy, Collegium Medicum, Jagiellonian University, Krakow

**Background:** Radiofrequency neurolysis of lumbar medial branch is one of the proven methods to treat patients with chronic lumbar zygapophysial joint pain, however, in some patients it can cause transient postoperative pain due to an inflammation caused by trauma of the electrode insertion and the thermal lesion around the target nerves. The aim of this presentation is to estimate the effectiveness of intraoperative injection of methylprednisolone or pentoxifylline in comparition to placebo (saline) in preventing this process.

**Methods:** 45 consecutive patients with chronic mechanical low back pain treated at the Department

of Pain Research and Therapy, Collegium Medicum, Jagiellonian University, Krakow were included. All patients randomly assigned into 3 groups of 15 patients each, were treated with radiofrequency neurotomy procedure and additionally with intraoperative local injection; in group 1 – methylprednisolone, group 2 – pentoxifylline, group 3 – saline, and were observed for 6 months. Pain intensity, summed pain intensity difference, minimum 50% reduction of pain intensity, Patients Satisfaction Score and local tenderness were determined.

**Results:** The 50% reduction of pain intensity was achieved in 80% patients one week after the procedure, and after 6 months such results were reported by 60% patients.. There was a significant reduction of pain intensity in all three groups compared to baseline, however, there were no differences between the three groups. There was a significant difference in local tenderness as a measure of postoperative pain in both, methylprednisolone and pentoxifylline groups. No other complications were observed.

**Conclusions:** Radiofrequency neurotomy is a safe and effective method to treat patients with zygapophysial joint pain. An additional injection of pentoxifylline and methylprednisolone can reduce postoperative pain commonly appearing after the procedure, however, neither pentoxifylline nor methylprednisolone influences long-term follow-up results of radiofrequency neurolysis of lumbar medial branch.

# High Grade Spondylolisthesis: Is reduction necessary?

D. SCHLENZKA
ORTON Orthopaedic Hospital, Helsinki/Finland

In **high grade spondylolisthesis (>50% slip)** the physiologic lumbosacral lordosis changes into a progressive kyphosis. The sagittal alignment of the spine is severely disturbed (pelvic retroversion, compensatory hyperlordosis). Some patients remain symptomfree despite the severe deformity. Others may develop root tension signs (hamstring tightness), back pain and/or leg pain, and neurological deficit. The patient suffers from a stiff gait and claudication.

Several reports in the literature present satisfactory clinical outcome after *in-situ* fusion as well as after reduction/fusion procedures. Major complications have been observed in 10 to 60 per cent of reduction cases.

A long-term follow-up study (mean 17.7 years) from the authors institution showed very satisfactory results in 69 patients after uninstrumented *in-situ* fusion. In this series, combined fusion was superior in comparison to anterior fusion alone or posterolateral fusion concerning subjective outcome and lumbosacral alignment (Lamberg et al 2006).

The proponents of reduction suggest that restoration of the sagittal contour of the lumbosacral junction is necessary to regain spinal balance and to overcome patient's subjective sypmtoms. However, according to the literature, considerable residual lumbosacral kyphosis of up to 55 degrees after reduction did not seem to have any negative effect on the clinical outcome (Bradford & Boachi-Adjei 1990, Poussa et al 1993, Hu et al 1996). Possibly, the capacity of the growing spine to adapt to the severe alignment changes is underestimated.

There are no randomised clinical studies available to date. Very few controlled studies comparing reduction/fusion with *in-situ* fusion have been published. Those studies failed to prove the benefit of slip reduction (Poussa et al 1993, Muschik et al 1997, Molinari et al 1999, Poussa et al 2006).

*In-situ* fusion remains the gold standard.

**Spondyloptosis (>100%)** is the real problem. The slipped vertebra is situated in front of the sacrum and durable *in-situ* fusion is difficult to achieve. In these cases partial reduction or vertebra resection according to Gaines may the considered if the local resources and surgeon's experience are adequate.

# Posterior Instrumentation and Fusion for Progressive Idiopathic Scoliosis

A. VON STREMPEL
Landeskrankenhaus Feldkirch (Austria)

Indication for surgery are prevention of progression of an idiopathic adolescent scoliosis. Structural improvement of the spinal column and correction of the trunk deformity for better cosmetic.

The Cobb angle should be 45° ore more.

Contraindications are poor general health, high anesthetic risk, severe osteoporosis.

**Surgical Technique**

The lateral deviation is straightened trough distraction and correction and stabilized with 1 rod. Two pedicle screws implanted at the caudal end of the rod assure its rotational stability. The amount of distraction corresponds to the lengthening of the spinal column as visualized on extension films according to Cotrel. Sublaminar wires inserted at the apex of the scoliosis help to approximate the deformed spine to the contoured rod.

**Results**

We followed up 67 out of 75 patients for at least 2 years (2 to 4 years). In 16 patients with a double major curve, the lumbar curve had been previously corrected with an anterior fusion. An average preoperative Cobb angle of 71,3° could be improved to 41,1°. No neurologic complications were noted. One patient died of a disseminated intravascular coagulopathy after an uneventful intraoperative course. Among complications we noted 2 pseudarthroses (with breakage of the rod), 1 asymptomatic rod breakage, 3 infections around the rod, 1 early infection, and 3 hematomas necessitating evacuation.

**Key Words**

Indipathic scoliosis – Progressive scoliosis – Posterior approach – 1-rod-technique – Stable instrumentation – Anterior derotation spondylodesis - Kyphoscoliosis

# Stabilization of the degenerated lumbar spine with the Cosmic system

A. VON STREMPEL
Landeskrankenhaus Feldkirch (Austria)

Clinical instability is defined as pathological displacement patterns which create pain deformities and neurological deficits. Disc-degeneration and facet arthritis lead to increase axial rotation motion.

A stable implant should control the displacement patterns (rotation/translation).

In the past the only surgical option was a fusion in situ or an instrumented spondylodesis. Cosmic is a Non Fusion implant-system which is non rigid but stable to control rotation and translation. The hinge between head and thread of the screw allows mikromovement in one direction, which creates some elasticity in the sagittal plan. The threaded part is covered by bonit which supports the ingrowth of the titan screw in the bone. In a finite element model the hinge-screw was compared to a rigid screw. The results show that the load in the hinge-screw is reduced, because of the load sharing effect between the anterior column and the implant system. In a lab test the system resisted 10 Mill. cycles 0,3 – 3,0 KN/1Hz, without implant failure or debris.

Indication for cosmic:

1. **Symptomatic spinal stenosis:** In these cases we do a conventional laminectomy, and if necessary fascieektomy, together with cosmic. We do not do reposition of a spondylolisthesis or of an other deformity.
2. **Recurrent discherniation:** In a second recurrence of a discherniation we decompress the nerve root together with a stabilisation.
3. **In combination with a fusion:** By a patient with a significant instability in the flexion/

extension X-rays and a second symptomatic segment we do a fusion in the significant unstable segment together with a non fusion stabilisation in the other one.

4. **To elongate an existing fusion:** Patients with a ridig 360 ° fusion develop quite often a symptomatic adjacent level degeneration. Than we use cosmic in the adjacent level if indicated together with a decompression.
5. **Stabilisation of a symptomatic degenerated disc disease:** These patients are typically middle-aged or even younger. We implant cosmic in a low invasiv-technique via the Wiltse approach.

Contraindications are patients with a significant deformity, which is responsible for the pain. In these cases the deformity needs to be corrected and we use cosmic together with a fusion. If a longer instrumentation is necessary the levels outside the corrected area can be stabilized in the non fusion technique.

Cosmic is used since 2002. More than 300 patients with more than 1500 screws were operated in Feldkirch. 181 patients have a follow up between 12 and 48 months. 107 patients (428 screws) got one level, 64 patients (384 screws) got two levels and 10 patients (80 screws) got three levels. We found four broken screws (0,6%), one broken rod (0,3 %) and 11 loose screws (1,2 %) which caused revision surgery in 9 patients (4,9 %). We did not see any screw dislocation. All implant failures appeared in the first 12 months.

We compared 75 patients of the non fusion group (NF) with 75 patients which were operated with SSCS together with a posterior lateral fusion (PLF). Follow up was 18 to 30 month. The patients age was 67,2 years (NF) and 55,9 years (PLF). Oswestry-score pre- and postoperatively was 25,4 / 17,0 (NF) and 23,7 / 14,7 (PLF). Pain on a analogue pain-scale from 0 to 10 was pre- and postoperatively 5,7 / 2,9 (NF) and analogue pain scale 5,8 / 3,4 (PLF). Hospital stay was 7,4 days (NF) and 16, 9 days (PLF). OR-time was 118,8 minutes (NF) and 172,4 minutes (PLF). Units of blood for transfusion were 0,60 (NF) and 2,96 (PLF). Complications were 12,1 % (NF) and 36,0 % (PLF).

Cosmic is a stable but non rigid non fusion system.

The surgical trauma is less compared to a fusion. The clinical results are equal to an instrumented posterior lateral fusion. Perioperatively there is less morbidity in the non fusion group.

The encouraging results are being confirmed in a multi-center study.

# Surgical management of high grade spondylolisthesis and spondyloptosis – 38 years experience

R. W. GAINES, Jr. (USA)

Low grade spondylolisthesis causes nuisance-grade back and leg pain which limits sports, leisure time and work-related participation. Patients with low grade spondylolisthesis are generally not "housebound."

For most patients who have it, high grade spondylolisthesis is a "crippling" condition which enforces a housebound lifestyle for most patients who are untreated. Occasionally, bowel and bladder paralysis occurs, due to cauda equina compression over the sacral dome. Symptoms may arise from the dense nerve root compression, from pain from the lumbosacral dislocation, from disc degeneration in the low lumbar spine, or from mid-lumbar impingement, due to secondary hyperlordosis, above the lumbosacral dislocation.

While a few patients apparently can live an active and productive lifestyle with untreated spondyloptosis, all the patients I have ever seen were functionally crippled by this unusual lumbosacral developmental dislocation.

I have been interested in spondyloptosis since 1969 when – as an orthopaedic resident – I had the opportunity to help manage and operate a teenager with a very, very severe spondyloptosis. In the following ten years, I also operated 4 other patients with very, very symptomatic spondyloptosis who were sent for treatment. My supervising surgeons and I did everything we knew how to do (that was in the literature) for these unfortunate people. Nothing we did for them helped them at all. As a matter-of-fact, two of our surgeries made our patients worse.

For purposes of this discussion, I will define high grade spondylolisthesis as at least grade 3 (by the Meyerding classification), with a slip angle of 20 degrees or more (by the classification of Boxall and Bradford.). Spondyloptosis is defined as the

most severe form of high grade spondylolisthesis, where – on a standing lateral spinal xray – the entire vertebral body of L5 sits below the top of S1. While the slip angle is always more than 20 degrees, for many patients, the "slip angle" is up to 75 degrees. The postural abnormality becomes progressively more abnormal as the slip angle increases. Sagittal plane malalignment reflects the severity of the vertebral dislocation, and hyperlordosis of the midlumbar spine becomes progressively more severe. In the most severe cases, a "crouch stance and gait" occurs. This occurs when the degree of posterior pelvic rotation exceeds the ability of the hip joint to hyperextend. When this "crouch stance and gait" occurs, the patients functional limitations become severe and the combination of severe nerve root pressure and spinal inefficiency render him housebound.

Since 1979, when I designed the L5 vertebrectomy with reduction of L4 onto S1 for the surgical management of patients with spondyloptosis, I may have become a referral source for the management of this very difficult spinal problem and have seen more and more patients with it. 4-6 patients present for evaluation and management every year. This exposure to many, many patients with high grade spondylolisthesis and spondyloptosis patients – some operated and some not operated – represents the "data base" on which this presentation is based.

In addition, since 1979, I have performed 40 "Gaines procedures" – that is, the resection of L5 with reduction of L4 onto S1 for the management of patients with severely symptomatic spondyloptosis. During that period, I have also managed a very similar number of patients with high-grade spondylolisthesis, but not spondyloptosis.

These patients were managed with several different techniques that evolved during the last 25 yrs.. In the 70's, the surgery included fusion-in-situ with iliac crest bone-graft. In the mid-80's, after pedicle screws were developed and the surgical techniques were perfected, I began to use them actively, along with anterior resection to improve the quality of reduction of the deformity, in a staged anterior resection/discectomy and then posterior reduction with pedicle screws. I had learned not to lengthen the spine or stretch the nerve roots from my experience with spondyloptosis. This "fundamental" of surgical management applies both to ptosis, as well as to high grade spondylolisthesis. The spinal column must not be lengthened, and the nerve roots must not be stretched.

Therefore, the "data base" of this report includes around 80 patients with high grade spondylolisthesis and/or spondyloptosis, with follow-up up to 38 years. I readily acknowledge that this report is not "unbiased" or "an independent review". However, the first 16 of my resection cases were independently reviewed and reported in SPINE in the early 90's.

This report will describe my current operative management of high grade spondylolisthesis and spondyloptosis in 2006.

HGS cases are operated by a staged reduction of L5 onto S1. The first stage consists of partial anterior L5-S1 discectomy and partial L5 vertebrectomy. No reduction is attempted. The abdominal wound is then closed and the patient turned prone for the posterior procedure. If the surgeon wishes to stage the procedure, the patient may be nursed, between stages, by log-rolling until the second stage is performed.

When the posterior procedure begins, pedicle screws are placed into the pedicles at L5 and S1. Posterior laminectomy of L5, L4 and S1are then performed, and any L5-S1 disc which impedes reduction is also removed. Reduction of L5 onto S1 is then performed with extensive nerve root exploration (beyond the foramen) to make certain that the L5 and the S1 roots and the dural tube are free and uncompressed, before L5 is reduced onto S1 using the pedicle screws. Interbody apposition generally leads to "bone-on-bone" healing between L5 and S1. A lateral spinal fusion is also performed, using the local bone graft obtained from the laminectomy and vertebrectomy. the cancellous graft is placed between the pedicle screws, and under the VSP plates. The nerve roots are re-examined, following the reduction, to make certain that they are free. The patient is generally left in bed, logrolling, for a month to permit preliminary healing of the spinal fusion before the patient is mobilized and rehabilitated.

For spondyloptosis, the resection procedure developed in 1979 remains the fundamental operative procedure. Extraordinary care is taken while removing the L5 pedicles to minimize L5 nerve root injury. L4 is gently reduced onto S1 with pedicle screws. Extra fixation is occasionally obtained in L3 for various reasons, and occasionally the abdomen is reopened and bone added into the L4-S1 interval, once the reduction of L4 onto S1 is achieved, if anatomic reduction is not possible.

All of the patients have been followed since their operative procedure to the present. One patient takes narcotics for pain relief after resection operative procedure. The need for the narcotics was his reaction to L5 dysaesthesias which were very bothersome for him. Many other patients have had similar dysaesthesias. Most patients manage those by ice packs, manual massage and Neurontin.

3 patients have had fibrous unions and broken screws. These have been successfully grafted and reinstrumented without losing any reduction. One patient has had retrograde ejaculation.

No patients have had any treatment for adjacent level degeneration with follow-up to 28 years. No patients have had treatment for any other spinal degeneration in the thoracic or lumbar spine.

Most of the patients are working, and many perform extraordinarily demanding occupations, including sports. While L5 nerve root irritation has been a common and seemingly unavoidable complication from this aggressive surgical management, the overwhelming majority of the nerve root related findings have spontaneously resolved within a few months to a year after the reconstruction.

No patients have ever said "I would never do this again, or "I wish I'd never done it."

Pre-operative counseling with 4-5 patients who have already had the surgery is the routine program for preparing new patients who inquire about having the reconstruction.

Under these circumstances, I continue to operate 1-2 patients every year for either HGS or spondyloptosis.

# Posterior approach for dens fracture

M. TĘSIOROWSKI, B. JASIEWICZ, E. LIPIK
Katedra i Klinika Ortopedii i Rehabilitacji CMUJ w Zakopanem
Kierownik prof. dr hab. med. Daniel Zarzycki

Fractures of axis are 7-15% of all fractures within the cervical spine, they may concern the odontoid process and tearing of joint capsule-ligament complex. Most often, especially at young people, injury is a cause – connected with car accident or diving. At the elderly, the basic cause of fracture is oncologic process – metastasis of primary tumour, infectious process or rheumatoid disease or osteoporosis (1,2).

The classification of odontoid fractures given by Anderson-d'Alonso consists of three types of injury localisation (3). Type I concerns the top of the odontoid process, this is an oblique, avulsion fracture. Type II is a fracture of C2 vertebral body at the level of the lower edge of anterior arch of C1, and type III is a fracture within C2 body at the base of dens.

Fractures of type II and III are always unstable fractures, with ligament complex and joint capsules tearing between C1 and C2 vertebra. In these types of fractures mechanism of the injury is lateral or postero-lateral, in which the skull and lateral massif of C1 are breaking the dens.

The aim of treatment is a stabile, anatomic healing of fractured vertebra without complications, such as delayed union, non-union, movement limitation, muscle or neurological deficiency and infection.

Posterior approach according to Brooks, with the stabilisation with wire loop in the treatment of spine fracture, enabled good bone healing, but holding C1, C2 vertebra stabilisation during bone graft healing was difficult, often bone graft resoprtion occurred as well as destabilisation and wire breakage.

After surgery, the limitation of rotational movements of cervical spine up to 50% occurred. This technique was not possible to apply at patients with fracture of posterior arch of C1.

Introducing of screw stabilisation according to Margiel or Roy-Camille improved the stability of fracture, allowed for: immediate, good fixation with posterior approach, possibility of operation in the case of C1 fracture and stabilisation of C1/C2 complex without occipito-cervical fusion (4).

Inserted screws may be placed in two ways: first, when the screw is running through intevertebral C1/C2 joint and the second, with independent screws inserted in C1 and C2 with posterior connector.

Technique of screw implanting is difficult, using of navigation system is advisable.

The development of implants allow for replacing long screws by bone anchors, fixed in lateral massif of C1 and articular process and arch of C2. Applying of anchors diminish the possibility of complications such as nervous or vascular damage.

Secondary dens fracture in the course of tumour, infection, rheumatoid disease or osteoporosis should be treated surgically from posterior approach, with pedicle stabilisation including occiput and atlanto-axial complex.

Dens fracture is oftem complicated with the non-union, and in these cases operation with posterior pedicle fusion of C1/C2 complex is the best solution.

References

1. *Brooks A.L., Jenkins E.B. Atlanto-axial arthrodesis by the wedge compression method. J. Bone Joint Surg. 1978, 60A, 279.*
2. *Clark C.R., White A.A. Fractures of the dens. A multicenter study. J. Bone Joint Surg. Am. 1985, 67, 1340-1348*
3. *Anderson L.D., d''Alonzo R.T. Fractures of the odontoid process of the axis. J. Bone Joint Surg. Am. 1974, 56, 1663-1674*
4. *Graham A.W., Swank M.L., Kinard R.E., Lowery G.L. Posterior cervical arthrodesis and stabilization with a lateral mass plate. Clinical and computed tomgraphic evaluation of lateral mass screw placement and associated camplications. Spine 1996, 21, 323-329*
5. *Tęsiorowski M., Zarzycki D., Ciupik L., Łabędzka A., Lipik E.; Kotwica potyliczna – nowy wszczep w stabilizacji potyliczno-szyjnej. Aspekty biomechaniczne i kliniczne. Ortop. Traum. Rehab. 2000, 2, 77-84.*

# Surgical treatment of compressive disorders of cranio-cervical junction. Decision making: to stabilize or not

M. GROCHAL, A. RADEK, M. RADEK, K. ZAPAŁOWICZ, J. KARBOWNIK, R. JEKIMOV, P. SKÓRA*
Klinika Neurochirurgii i Chirurgii Nerwów Obwodowych
*Zakład Anastezjologii i Intensywnej Terapii 2 Szpitala Klinicznego im. WAM Uniwersytetu Medycznego, Centralny Szpital Weteranów w Łodzi

The cranio-cervical junction is a complex system allowing for 3D head movements. Stabilization of C1-C2 or O-C1 can completely and permanently eliminate mobility of this junction. In the treatment of disorders with instability of the cranio-cervical junction, the procedure consists of decompression and stabilization. There are however, many disorders causing stenosis of the cranio-cervical junction (bone tumors or tumors of the nervous system), removal of which can result in jatrogenic destabilization.

The authors present clinical cases and approaches, which usually do not require necessity of internal fixation of the cranio-cervical junction or allow for putting this necessity away. The advantages and disadvantages of different used by authors systems of fixation are also presented.

# Minimally invasive percutaneous kyphoplasty

K. ZAPAŁOWICZ, A. RADEK
Department of Neurosurgery and Surgery of Peripheral Nerves
Medical University of Lódź, University Hospital Nr 2
Żeromskiego 113 St., 90-549 Lódź, Poland
Head: professor Andrzej Radek, MD.

**Introduction.** The authors present their personal experience with kyphoplasty. Percutaneous kyphoplasty means minimally invasive method, developed in 1998 year. Since then kyphoplasty is widely used. This method is mainly indicated in treatment of kyphotic deformity due to osteoporotic vertebral compressive fractures. Kyphoplasty is also indicated in certain cases of spinal trauma and tumors. The first step of method is bilateral insertion of balloons in vertebral body. Expandable balloons provoke internal pressure in vertebral body. This is the way to decrease vertebral collapse and to reduce kyphosis. When vertebral body is expanded, balloons are removed and empty space is filled with cement – polymethylmethacrylate (PMMA). PMMA is administered with relatively low pressure, which reduce possibility of extravertebral leakage and embolism.

**Material and methods.** In November 2005 in Author's Department for the first time in Poland kyphoplasty was realized. Until end of June 2006 seven patients were treated. The age of patients varied from 21 to 84 years (mean – 49 years); 12

vertebral bodies were filled with PMMA. The indications for kyphoplasty were as follows: osteoporotic compressive fractures – 4 (3 female, 1 male), traumatic compressive fracture of Th-4 – 1 male, vertebral hemangioma – 2 female patients. In 2 cases kyphoplasty was performed in general anesthesia and in 5 other in local anesthesia. For treatment of hemangioma of C-7 right anterior approach was used, allowing access between sternocleidomastoid muscle and trachea. In 6 other cases typical posterior intrapedicular or extrapedicular approach was used.

**Results.** The clinical results were based on follow-up examinations, Oswestry questionnaire and Visual Analog Pain Scale. For radiological estimation plain roentgenograms or CT were realized. Follow-up examinations revealed pain relief in all cases. No complications were observed.

**Conclusions.** Percutaneous kyphoplasty is well-tolerated by patients. The results proven pain relief in cases of osteoporotic compressive fractures. Kyphoplasty can be successfully used in certain cases of traumatic lesions or spinal hemangionas.

# New trends in the treatment of totally traumatic spinal cord lesions in particular olfactory ensheating cells (OECs) transplantations – expectations and hopes

W. JARMUNDOWICZ, P. TABAKOW, R. MIĘDZYBROCKI
Katedra i Klinika Neurochirurgii, Akademia Medyczna we Wrocławiu

**Summary**
Understanding of lesions' pathophysiology in both central and peripheral nervous system is impossible without studying of the neural regeneration mechanisms. A unique feature of highly accurate synaptic re-joining of an affected nerve is seen in the nervous systems of many animal species. Many differences in regeneration are observed, depending on either central or peripheral system involvement.

The objective of this lecture is to present the *events* in the peripheral and central nervous system (CNS) in the time of injury, with special emphasis on regeneration processes. Current opinions on the treatment of peripheral nerves' and spinal cord injuries will also be presented. A role of unique population of macroglial cells – olfactory ensheating cells as regeneration stimulants in the injured spinal cord in adult mammals will be discussed especially.

Cutting of an axon in the peripheral nerve evokes set of degenerative events in its efferent part already described by Waller, while regenerative processes are seen in both afferent part of the axon and neuron body. The aim of these changes is functional restitution of the axon. The only must is end-to-end anastomosis of the affected axon. Central neuron's injury is completely different. Minimal neural regenerative changes give no functional improvement in the place of injury. Such situation is met in total spinal cord injuries. In these cases our objective in functional improvement was so called neuroprotection both surgical and pharmacologic as well as rehabilitation.

In the cases of total spinal cord injuries function of the long pathways of spinal cord are lost and cannot be regained. That is why intensive studies began in the mid-80"s of 20th century to discover negative factors of neural regeneration and positive stimulants of the axon regeneration in the CNS. Emphasis was made on spinal cord studies, since it was most often affected by irreversible lesions leading to a tremendous handicap.

**Known inhibiting factors of the central neuron's regeneration**
A known experiment of incision of a 9-day opossum's (a primitive mammall, Didelphidae) spinal cord confirms axons' regeneration and functional recovery in an immature cord. Regeneration phenomenon is not observed in a 12 week opossum. A capital difference in spinal cord histology is presence of a myelinated sheath around the axons in the older animal. Loss of spontaneous regenerative potential in CNS of the adult mammals is strictly connected with the role of central glial cells like oligodendrocytes, astrocytes and microglia. During maturation oligodendrocytes are able to myelinate the axons of central neurons. However, central myelin contains proteins inhibiting axons' regrowth. They are commonly known as Nogo-family or myelin-associated proteins (MAP) like

NJ-35 and NJ-250. Another inhibiting factor is missing trophic activity of oligodendrocytes and astrocytes on central neurons. Reactive gliosis in the injured place is also important.

**Methods of induction of regeneration in CNS.**

1. Local application of neurotrophic agents (inducing regeneration genes in the place of injury and inhibiting neuron's death).
2. Application of antibodies inhibiting central myelin proteins .
3. Direct intraspinal transplantation of the cells of neurotrophic potential

**Cellular populations of neurotrophic potential experimentally transplanted to an ischaemic region of spinal cord**

1. stem cells,
2. Schwann's cells,
3. fetal neurons,
4. activated macrophages,
5. hypothalamic tanicytes
6. genetically modified cells producing neurotrophines
7. olfactory ensheating cells

Among the mentioned cells special attention deserve olfactory ensheating cells (OECs), described by Golgi and Blanes in 19th century. They stend a separate population of macroglia present in both peripheral and central part of the olfactory pathway. Their exact function had been studied in the early 80'of 20th century. OECs are responsible for generation of new olfactory receptor neurons from the basal precursor cells occurring in the olfactory epithelium in adult mammals ever 4-8 weeks.

Some histochemical and morphologic features of astrocytes and Schwann's cells are met in the OECs. Their embryogenesis is quite alike Schwann's cells, from the peripheral nervous system's structures. They have identical ability of creation of myelin sheath and their cellular membrane contains a low-affinity receptor for neuronal growth factor (p75-NGFR).

**Experimental studies on OECs transplantation to an cut spinal cord in a rat**

These studies were run for the first time by a Spanish team of neurobiologists guided by Almudeny Ramon-Cueto. A good result in regeneration and functional motoric recovery were observed in transplantation of the OECs to either cut dorsal ganglion of a nerve or to place of incision in the thoracic part of spinal cord. With the descending method numerous axons directing to the distal spinal cord were found. In further observation the axons myelinated and organized regular pathways parallel to the longitudinal axis of spinal cord. A characteristic feature of OECS was their ability to myelinate significantly long sections along white and grey matter of the spinal cord.

OECs secrete many neurotrophic factors, like NGF, BDNF, NT-3, PDGF and neuropeptide-Y. These agents activate genes conditioning regeneration (RAG – regeneration activated genes). In the injured place they inhibit proliferation of oligodendrocytes and astrocytes thus preventing from glial scar formation.

**Perspectives of OECs application in the treatment of spinal cord injuries in humans**

Encouraging results obtained in animal models form a basis for a consideration about use of OECs in humans. They are preceded by studies on the transplantation effects in apes.

Before OECs will be used in humans few problems must be solved. These include source of OECs, technique of collecting, effective isolation, proliferation and culturing methods. Another problems are: defining of the "therapeutic window" after the injury and immunosupresion in allotransplantation.

The results of OECs transplantation are judged currently in research centers in Australia by Macky-Sim and by Carlos Lima in Portugal.

**Own experiences**

Since 2004 Department and Clinic of Neurosurgery in Medical School in Wroclaw together with Institute for Immunology and Experimental Therapy of Polish Academy of Sciences in Wroclaw perform a research on isolation and culturing of the mature human OECs collected from olfactory membrane and olfactory bulb. The material is sampled during organs explantation procedure from the cadavers. Collection of OECs from the olfactory region in the nasal cavity is possible from patients qualified for olfactory-spinal transplantation. Already obtained results confirm possibility of isolation and culturing OECs in our conditions. Preliminary experiments in animal models proved safety of the method and survival of the OECs after their transplantation.

Currently we are preparing for the first OECs transplantation in humans. First patients are already selected. Our research is approved by Bioethics Commission and supported by a grant from Committee for Scientific Research.

# Failed back Surgery Syndrome

D. ZARZYCKI
Chair and Clinic of Orthopaedics and Rehabilitation, Collegium Medicum of Jagiellonian University; University Hospital of Orthopedics and Rehabilitation in Zakopane

**Summary**
Incidence of the back pains In the age group of 10-85 years is estimated as 40%. Around 25% of these people seek for medical counseling, some 90% of them will recover and get back to work within 6 weeks. Those uncured ones after a six month conservative treatment will become a relatively big and socially important group of surgical patients; such patients could be referred to as chronic. Specialists in orthopedics and neurosurgery always advise surgical treatment in such conditions. In all the surgical methods of the treatment of back pains a success is achieved in as far as 60% of patients only.

Reasons of failures.
1. Disrespect attitude to the imperfect diagnostic methods in identifying of the source of the pain.
2. Disregard to the lack of scientific evidences in different methods' efficacy.
3. Unavailing belief in novel medical technologies and orthopedic implants
4. Lack of criticism to the published data on surgery effectiveness – especially to revisory *(explorative?)* surgery.
5. Disrespect to evidences proving psychosocial factor's importance, especially in the patients qualified for re-operation.

Common causes of complications:
1. wrong selection of the patients
2. wrong diagnosis and improper surgical technique
3. operators' mistakes

Complication after a primary surgical treatment
1. intraspinal hematoma
2. spondylodiscitis
3. pseudomeningocoele
4. radiculitis (20% within 6 weeks after surgery, 2% after six months)
5. arachnoiditis (sterile in 6%-16%)
6. textiloma
7. stenosis of either vertebral canal or intervertebral foramen

Chanses for success in re-operation reach 60-82% in the intervertebral disc prolapse, whereas in meningeal cicatrices are only at 17-38%. The reason why, is that vertebral canal with its enclosed structures react badly to any form of intervention.

# Stabilization of odontoid fractures by anterior approach

K. ZAPAŁOWICZ, A. RADEK, M. RADEK
Department of Neurosurgery and Surgery of Peripheral Nerves, Medical University of Lodz, University Hospital Nr 2 "WAM", Street: Zeromskiego 113, 90-549 Lodz, POLAND

**Introduction.** Odontoid base fractures type II according to classification by Anderson and D'Alonzo, mostly are treated surgically. However there are controversies about method of surgical treatment.

**Material and Methods.** The authors present method of direct odontoid osteosynthesis by screw This method was described previously by Böhler and Nakanishi. The advantages of Anterior approach to the fractured odontoid is great advantage of this method. The authors compare effectiveness of direct odontoid osteosynthesis with C1-C1 fixations by posterior approach. They present series of 7 cases operated on by anterior approach. The pitfalls and complications of different methods used for treatment of odontoid type II fractures are also discussed.

Results. In author's material 6 cases were treated successively, stable fusion was achieved. The range of head motion was estimated as unlimited by surgery. The range of In 1 case osteolysis of odontoid peg around the screw led to nonunion. In this case fixation of C1-C2 was realized.

Conclusions. Direct screw fixation of odontoid base fractures is safe and effective method of treatment.

# Current opinions on methylprednisolone therapy in acute spinal cord injury and alternative pharmacological treatment.

T. POTACZEK, K. KĄCKA
Department of Orthopaedic Surgery and Rehabilitation
Jagiellonian University, College of Medicine, Zakopane 34-500, Balzera str. 15
Chair of Department: prof. Daniel Zarzycki

**Introduction:** Acute spinal cord injuries (ASCI) and their consequences still are a challenge for doctors of various specialities. Current concepts of ASCI pathophysiology underline the role of secondary damage therein membrane lipid peroxydation and nerve cells apoptosis. Hopes for effective decrease of these phenomenons were bound with methylprednisolone therapy after encouraging results of American NASCIS I, II and III trials. Presently methylprednisolone treatment is widely discussed and the efficacy is uncertain.

**Aim of paper**: Authors basing on current literature present concepts of posttrumatic changes in spinal cord after ASCI, mechanisms of methylprednisolone action, advantages and disadvantages of this therapy. Based on long term observations methylprednisolone treatment does not fulfil expectations, furthermore NASCIS trials lack accurate evaluation and adverse reactions like gastro-intestinal bleeding, infections and prolonged hospitalisation outweigh benefits.

Future directions of pharmacological treatment are presented.

**Conclusion:** All gathered data suggest that methylprednisolone therapy in ASCI is not efficient and can not be treated as therapeutical standard. Initial results of methylprednisolone therapy were not confirmed in following studies.

Current pharmacological research is focused on neuroprotective and antioxidant treatment e.g. erythropoetin, estrogen or activated autologic macrophages.

# Thoracolumbar ($Th_{11}$ – $L_2$) fracture treatment. Criteria: type of construction long or short instrumentation

D. ZARZYCKI, E. LIPIK
Ośrodek: Katedra i Klinika Ortopedii i Rehabilitacji UJ CM
Kierownik: prof. dr hab. med. Daniel Zarzycki

Uniwersytecki Szpital Ortopedyczno – Rehabilitacyjny, ul. Balzera 15, 34 – 500 Zakopane
tel. (0 18) 20 142 97, fax (0 18) 20 146 18, e-mail: sekretariat@klinika.net.pl

**Abstract**

Applying traumatic forces to the spine leads to compressive, flexion or rotational fractures concentrated mainly at the junctional zones.

The individual elasticity of the tissues in thoracolumbar spine and the kind of forces determine whether the injury affects the bones, ligaments and/or the intervertebral discs.

No fracture can be appropriately treated until it is evaluated and classified. A widely accepted classification is the AO classification (Magerl et al., Euro Spine J. 1994), compression fracture (type A 66,1%).

**Type A** - involve vertebral body it is a compression injury anterior or posterior part of vertebrae:

Type $A_1$ fracture is crumpling of the body next to the endplate
Type $A_2$ split fracture
Type $A_3$ burst fracture
$A_{3.1}$ incomplete burst fracture
$A_{3.2}$ complete burst fracture

Options of treatment:

1. Treatment focuses on restoring and maintaining the saggital profile.

2. Compression of the anterior column with significant segmental kyphosis required restoration of anterior column with additional posterior stabilization.
3. In all type A fractures only one level fusion is required.

**Type B** – distraction fracture (14,5%)

The severity of posterior element injury determines the extent of fusion.

Type $B_1$ intraarticular flexion – distraction fracture

Type $B_2$ it is osseous disruption of the intraarticular portion of the lamina and pedicles propagating into vertebral body

Type $B_3$ fracture of anterior and posterior columns of the spine with distraction

Options of treatment:

Type $B_1$ one level posterior fusion

Type $B_2$ one level posterior fusion

Type $B_3$ more than two levels of posterior instrumentation

**Type C** – rotation fracture of anterior and posterior columns of spine (19,4%).

This is the most unstable fracture, fusion of at least two segments is required. Posterior spine instrumentation is recommended.

Conclusion

The goal of surgical treatment of thoracolumbar fracture should be:

1. Immediate stabilisation.
2. Restoration and maintenance of saggital alignment.
3. Decompression of spinal canal if required.
4. Construction of instrumentation depends on the injured segment.